

Journal of Clinical and Basic Cardiology

An Independent International Scientific Journal



Journal of Clinical and Basic Cardiology 2000; 3 (2), 99-101

Long-term results of coronary balloon angioplasty in unstable angina pectoris

Halon DA, Flugelman MY, Lewis BS, Merdler A, Rennert H
Shahla J

Homepage:

www.kup.at/jcbc

**Online Data Base Search
for Authors and Keywords**

Long-Term Results of Coronary Balloon Angioplasty in Unstable Angina Pectoris

D. A. Halon, M. Y. Flugelman, A. Merdler, H. Rennert¹, J. Shahla, B. S. Lewis

Increased levels of systemic inflammatory markers, that predate the acute event in many patients with unstable angina pectoris, may suggest a tendency for recurrent events in unstable patients. We examined the long-term (10–12 years) outcome of a cohort of patients revascularized by balloon angioplasty for stable or unstable angina pectoris in 1984–1986. Despite a small early hazard in unstable patients subsequent survival was the same in both groups (71 % in unstable and 81 % in stable patients at 11 years, NS). Event-free survival (alive, no myocardial infarction or repeat revascularization) was the same in both groups (32 % at 10 years). Even after subgroup analysis using the Braunwald classification we found no tendency for a greater incidence of late events in the unstable cohort. *J Clin Basic Cardiol 2000; 3: 99–101.*

Key words: PTCA, unstable angina pectoris, long-term outcome

The clinical syndrome of unstable angina pectoris is characterized by new recurrent episodes of ischaemic pain at rest or on minimal effort in the absence of evidence for myocardial infarction. Unstable angina appears to be related to a structural change in a previously stable, generally non-obstructive, coronary atheromatous plaque as a result of fissuring (rupture) or erosion, with local platelet aggregation and thrombus formation overlying and adherent to the plaque [1–5]. Recurrent episodes of chest pain may be associated with distal embolization of thrombotic material causing minor myocardial damage and an increase in serum troponin I and troponin T levels [6]. These patients represent a subset with a higher risk of further adverse events.

The syndrome of unstable angina pectoris is often accompanied by systemic signs of inflammation. A raised C-reactive protein level [7] and interleukin-6 [8] are associated with an unfavourable outcome and Liuzzo et al. [9] have shown that increased plasma levels of CRP may predate the clinical syndrome. Neri Serneri et al. [10] demonstrated lymphocytic activation, not consequent to myocardial ischaemia, supporting the immune system mediated, inflammatory nature of unstable angina. This activation persisted for 6–8 weeks. Merlini et al. [11] demonstrated increased coagulation system activity during the acute phase of unstable angina and a persistent hypercoagulable state over 6 months despite an uneventful clinical course.

The incidence of short- and medium-term recurrent cardiovascular events is increased in certain angiographic subsets of patients undergoing coronary balloon angioplasty [12–14]. The more recent observations of systemic inflammatory and coagulation abnormalities in patients with unstable angina led us to question whether the long-term outcome after angioplasty would be detrimental in patients with angina pectoris, since these systemic manifestations, often persisting for several months, may represent a persistent tendency to plaque vulnerability, recurrent acute coronary syndromes and/or late coronary restenosis. To test this hypothesis, we examined the long-term (10–12 years) outcome in patients with unstable angina treated by balloon angioplasty and compared the findings with those of patients with stable angina undergoing angioplasty during the same time period.

Patients and methods

During the 3 year period 1984–86 coronary balloon angioplasty was attempted in 224 consecutive patients and completed in 199 of them. In 14 patients the procedure was performed in the context of recent acute myocardial infarction without evidence of recurrent angina or ischaemia and these patients were excluded from the present analysis. Unstable angina was present in 64 patients and stable angina in 121. Baseline clinical and angiographic characteristics were similar in the stable and unstable groups (Table 1). Follow-up for survival was available in all patients at a mean of 11.1 ± 0.7 years.

Event-free survival was ascertained at a mean of 9.5 years. Long-term survival was assessed using Kaplan–Meier curves and the log rank test. Recurrent events (infarction or revascularization) were compared by annual event rates. Dichotomous variables were compared by 2×2 tables and continuous variables by Student's *t* test. The study had greater than 80 % power to detect a clinically significant 20 % difference in survival and 20 % difference in event-free survival between the stable and unstable patient groups.

Results

There was a small early hazard in patients with unstable angina due to higher mortality in patients with post infarction

Table 1. Baseline characteristics of patients with stable and unstable angina pectoris

| | Unstable angina (n = 64) | Stable angina (n = 121) | p value |
|---|--------------------------|-------------------------|---------|
| Age (yrs) | 58.4 \pm 9.2 | 55.9 \pm 10.0 | NS |
| Male | 45 (70.3 %) | 94 (77.7 %) | NS |
| Previous infarction | 34 (53.1 %) | 52 (43 %) | NS |
| Multivessel disease | 33 (51.6 %) | 62 (51.2 %) | NS |
| Diabetes mellitus* | 13 (20.6 %) | 25 (21 %) | NS |
| History of hypertension* | 20 (31.7 %) | 43 (36.1 %) | NS |
| Mean no. (\pm SD) of systems dilated | 1.2 \pm 0.38 | 1.2 \pm 0.48 | NS |
| Complete revascularization | 31 (61 %) | 74 (61 %) | NS |

*unstable angina n = 63; stable angina n = 119

tion angina and heart failure. Subsequent survival was the same for the stable and unstable groups so that at 11 years survival was 71 % in unstable patients and 81 % in stable patients, NS) (Fig. 1). The yearly rates of adverse events (acute infarction or revascularization) are shown in Fig. 2 averaged over each 2 year period. Event rates for stable and unstable patients were not significantly different at any time during the follow-up period. Event-free survival (alive without myocardial infarction or repeat revascularization) was the same in both cohorts (32 % at 10 years).

We retrospectively defined subgroups of unstable patients at increased short term risk using the Braunwald classification and found a similar long-term survival in patients in Braunwald class 3 and classes 1 and 2 combined (85 % vs 80 % at 10 years, NS) and event-free survival (43 % for both at 10 years). In a subgroup in which electrocardiographic (ECG) data were available and in whom ischaemic ECG changes were identified during the index hospitalization, 10 year survival was similar to those without these ECG changes (81 % vs 85 %, NS) and event-free survival was 56 % vs 55 % (NS).

Discussion

Increased risks were initially reported in patients undergoing angioplasty for unstable angina pectoris, due to an increased incidence of thrombus and instability of the plaque [15]. For this reason, we and many other centers usually attempt to stabilize patients prior to angiography, although it is not altogether proven [16, 17] that outcome is improved by delaying intervention. Stammen et al. [18] performed angioplasty in patients with unstable angina at a mean of 15 (range 1-76) days after hospital admission and reported a similar 6 month outcome to that in patients with stable angina.

A higher incidence of restenosis following balloon angioplasty in unstable patients has been described by some [19, 20] but not all [13] authors. Local lesion characteristics may influence the early response to angioplasty and late event rate [13, 14, 21-23]. In the National Heart, Lung and Blood Institute Angioplasty registry the cumulative event rate at 2 years was the same for unstable and stable patients [24], but at 5 years a higher crude mortality was reported in patients with rest angina than in unstable patients without rest angina and particularly in those with post-infarction angina [25].

The present analysis highlighted the potential early hazard of coronary balloon angioplasty in patients with Class IIIB unstable angina in the mid-1980's, but showed quite clearly that the later course is not different from that of stable patients. The findings confirmed the shorter-term reports that coronary angioplasty was effective in patients with unstable angina pectoris [13, 15, 24, 26] even though angioplasty of the obstructive coronary lesion does not prevent the systemic reaction and its local disruptive nature could amplify it. We did not observe an increased number of recurrent acute adverse events compared with patients treated for stable angina. Events were similar in the stable and unstable cohort when we examined freedom from any event or patient events on an annual basis, thereby examining and including recurrent events in the same patient.

The present study provided, then, no evidence that after an index episode of unstable angina patients were at increased long-term risk for further adverse events compared to stable patients after coronary balloon angioplasty. Many determinants of increased susceptibility of plaques to rupture have been identified such as a large lipid core, thin fibrous cap and evidence of macrophage infiltration and digestion of cap collagen [27-29]. Markers of acute systemic inflammation, increased coagulation tendency and infectious agents probably have some role in the aetiology or modulation of ischaemic syndromes [9, 11, 30-32], but factors modulating response to the acutely unstable plaque may be different to those responsible for repeat late coronary events. It appears that the beneficial effect of mechanical reperfusion far superceded any tendency to recurrent acute syndromes, albeit we did observe an increased tendency to restenosis in a subset of patients with multiple coronary irregularities, decreased coronary flow or angiographic intracoronary thrombus [13].

In the current era of antiplatelet glycoprotein 2b/3a inhibitors, clinical stabilization may be more readily achieved prior to intervention in unstable patients [33]. The CAPTURE study showed that use of the 2b/3a glycoprotein receptor blocker abciximab 24 hours before intervention decreased the risk of myocardial infarction [34]. In addition, coronary stenting, and the greatly improved imaging by radiography and intravascular ultrasound in recent years, allow for optimization of the dilated lesion at the time of percutaneous intervention [35]. These advances in the management of high risk unstable patients should further de-

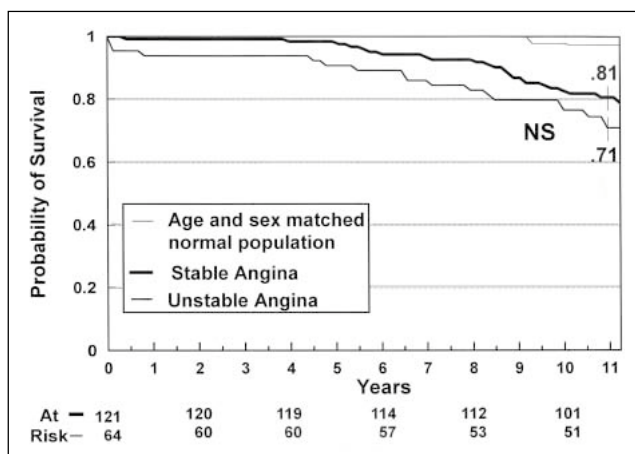


Figure 1. Kaplan-Meier curves of survival for patient cohorts with stable and unstable angina pectoris. After a small early fall in survival of unstable patients the curves remained parallel throughout the follow-up period, with no difference in long-term survival between the 2 groups.

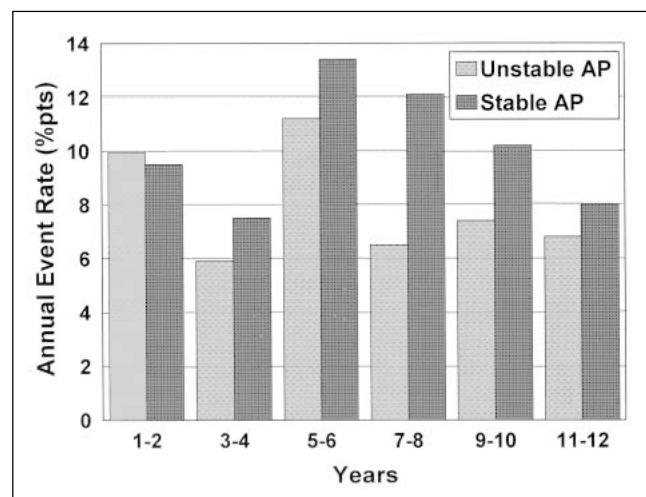


Figure 2. Annualized event rate (averaged for each 2 year period) in patients with unstable and stable angina pectoris. There was no difference in recurrent events between the 2 groups.

crease the potential disadvantage of performing angioplasty in the presence of an acute coronary syndrome.

References:

1. Davies MJ, Thomas AC. Plaque fissuring: the cause of acute myocardial infarction, sudden ischemic death and crescendo angina. *Br Heart J* 1985; 53: 363-73.
2. Fuster V, Badimon L, Badimon JJ, Chesebro JH. The pathogenesis of coronary artery disease and the acute coronary syndromes. *N Engl J Med* 1992; 326: 310-8.
3. Farb A, Burke AP, Tang AL, Liang TY, Mannan P, Smialek J, Virmani R. Coronary plaque erosion without rupture into a lipid core. A frequent cause of coronary thrombosis in sudden coronary death. *Circulation* 1996; 93: 1354-63.
4. Burke AP, Farb A, Malcom GT, Liang YH, Smialek J, Virmani R. Coronary risk factors and plaque morphology in men with coronary disease who died suddenly. *N Engl J Med* 1997; 336: 1276-82.
5. Flugelman MY, Virmani R, Correa R, Yu Z, Farb A, Leon MB, Elami A, Fu Y, Casscells W, Epstein SE. Smooth muscle cell abundance and fibroblast growth factors in coronary lesions of patients with nonfatal unstable angina. A clue to the mechanism of transformation from the stable to the unstable clinical state. *Circulation* 1993; 88: 2493-500.
6. Lindahl B, Venge P, Wallentin L. Troponin T identifies patients with unstable coronary artery disease who benefit from long-term antithrombotic protection. *J Am Coll Cardiol* 1997; 29: 43-8.
7. Haverkate F, Thompson SG, Pyke SD, Gallimore JR, Pepys MB. Production of C-reactive protein and risk of coronary events in stable and unstable angina. European Concerted Action on Thrombosis and Disabilities Angina Pectoris Study Group. *Lancet* 1997; 349: 462-6.
8. Biasucci LM, Vitelli A, Liuzzo G, Altamura S, Caligiuri G, Monaco C, Rebuzzi AG, Ciliberto G, Maseri A. Elevated levels of interleukin-6 in unstable angina. *Circulation* 1996; 94: 874-7.
9. Liuzzo G, Biasucci LM, Rebuzzi AG, Gallimore JR, Caligiuri G, Lanza GA, Quaranta G, Monaco C, Pepys MB, Maseri A. Plasma protein acute-phase response in unstable angina is not induced by ischemic injury. *Circulation* 1996; 94: 2373-80.
10. Neri Semeri GG, Prisco D, Martini F, Gori AM, Brunelli T, Poggesi L, Rostagno F, Gensini GF, Abbate R. Acute T-cell activation is detectable in unstable angina. *Circulation* 1997; 95: 1806-12.
11. Merlini PA, Bauer KA, Oltrona L, Ardissino G, Cattaneo M, Belli C, Manucci PM, Rosenberg R. Persistent activation of coagulation mechanism in unstable angina and myocardial infarction. *Circulation* 1994; 90: 61-8.
12. Ambrose JA, Winters SL, Stern A, Eng A, Teicholz LE, Gorlin R, Fuster V. Angiographic morphology and the pathogenesis of unstable angina pectoris. *J Am Coll Cardiol* 1985; 5: 609-16.
13. Halon DA, Merdler A, Shefer A, Flugelman MY, Lewis BS. Identifying patients at high risk for restenosis after percutaneous transluminal coronary angioplasty for unstable angina pectoris. *Am J Cardiol* 1989; 64: 289-93.
14. Chen L, Chester MR, Crooke R, Kaski JC. Differential progression of complex and smooth stenoses within the same coronary tree in men with stable coronary artery disease. *J Am Coll Cardiol* 1995; 25: 837-42.
15. De Feyter PJ, Serruys PW, van den Brand M, Balakumaran K, Mochtar B, Soward AL, Arnold AER, Hugenholz PG. Emergency coronary angioplasty in refractory unstable angina. *N Engl J Med* 1985; 313: 342-6.
16. Anderson HV, Cannon CB, Stone PH, Williams DO, McCabe CH, Knatterud GL, Thompson B, Willerson JT, Braunwald E. One-year results of the thrombolysis in myocardial infarction (TIMI) IIIB clinical trial. A randomized comparison of tissue-type plasminogen activator versus placebo and early invasive versus early conservative strategies in unstable angina and non-Q wave myocardial infarction. *J Am Coll Cardiol* 1995; 26: 1643-50.
17. Antoniucci D, Santoro GM, Bolognese L, Leoncini M, Buonamici P, Valenti R, Fazzini PF. Early coronary angioplasty as compared with delayed coronary angioplasty in patients with high-risk unstable angina pectoris. *Coron Artery Dis* 1996; 7: 75-80.
18. Stammen F, Scheerder I, Glazier JJ, Van-Lierde J, Vrolix M, Willems JL, De Geest H, Piessens J. Immediate and follow-up results of the conservative coronary angioplasty strategy for unstable angina pectoris. *Am J Cardiol* 1992; 69: 1533-7.
19. Serruys PW, Luijten HE, Beatt KJ, Geuskens R, de Feyter PJ, van den Brand M, Reiber JHC, Ten Katen HJ, van Es GA, Hugenholz PG. Incidence of restenosis after successful coronary angioplasty: a time-related phenomenon. *Circulation* 1988; 77: 361-71.
20. Plokker HWT, Ernst SMPG, Bal ET, van den Berg ECJM, Mast GEG, van der Feltz TA, Ascoop CAPL. Percutaneous transluminal coronary angioplasty in patients with unstable angina pectoris refractory to medical therapy: long-term clinical and angiographic results. *Cathet Cardiovasc Diagn* 1988; 14: 15-8.
21. de Groote P, Bauters C, McFadden EP, Lablanche JM, Leroy F, Bertrand ME. Local lesion related factors and restenosis after coronary angioplasty. Evidence from a quantitative coronary angiographic study in patients with unstable angina undergoing double vessel angioplasty. *Circulation* 1995; 91: 968-72.
22. Kaski JC, Chester MR, Chen L, Katritsis D. Rapid angiographic progression of coronary artery disease in patients with angina pectoris. The role of complex stenosis morphology. *Circulation* 1995; 92: 2058-65.
23. Chester MR, Chen L, Kaski JC. The natural history of unheralded complex coronary plaques. *J Am Coll Cardiol* 1996; 28: 604-8.
24. Bentivoglio LG, Holubkov R, Kelsey SF, Holmes DRJ, Sopko G, Cowley MJ, Myler RK. Short and long term outcome of percutaneous transluminal coronary angioplasty in unstable versus stable angina pectoris: a report of the 1985-1986 NHLBI PTCA Registry. *Cathet Cardiovasc Diagn* 1991; 23: 227-38.
25. Bentivoglio LG, Detre K, Yeh W, Williams DO, Kelsey SF, Faxon DP. Outcome of percutaneous transluminal coronary angioplasty in subsets of angina pectoris. A report of the 1985-1986 National Heart, Lung and Blood Institute percutaneous transluminal coronary angioplasty registry. *J Am Coll Cardiol* 1994; 24: 1195-206.
26. Morrison DA, Bies RD, Sacks J. Coronary angioplasty for elderly patients with "high risk" unstable angina: Short-term outcomes and long-term survival. *J Am Coll Cardiol* 1997; 29: 339-44.
27. Fuster V, Badimon L, Badimon JJ, Chesebro JH. The pathogenesis of coronary artery disease and the acute coronary syndromes (1). *N Engl J Med* 1992; 326: 242-50.
28. Fuster V, Badimon L, Badimon JJ, Chesebro JH. The pathogenesis of coronary artery disease and the acute coronary syndromes (2). *N Engl J Med* 1992; 326: 310-8.
29. Theroux P, Fuster V. Acute coronary syndromes: unstable angina and non-Q wave myocardial infarction. *Circulation* 1998; 97: 1195-206.
30. Mach F, Lovis C, Gaspoz J-M, Unger P-F, Bouillie M, Urban P, Rutishauser W. C-reactive protein as a marker for acute coronary syndromes. *Eur Heart J* 1997; 18: 1897-902.
31. Ridker PM, Cushman M, Stampfer MJ, Tracy RP, Hennekens CH. Inflammation, aspirin and the risk of cardiovascular disease in apparently healthy men. *N Engl J Med* 1997; 336: 973-9.
32. Maass M, Bartels C, Engel PM, Mamat U, Sievers H-H. Endovascular presence of viable Chlamydia pneumoniae is a common phenomenon in coronary artery disease. *J Am Coll Cardiol* 1998; 31: 827-32.
33. Hamm CW, Heeschen C, Goldmann B, Vahanian A, Adgey J, Miguel CM, Rutsch W, Berger J, Kootstra J, Simoons ML. Benefit of abciximab in patients with refractory unstable angina in relation to serum troponin T levels. *N Engl J Med* 1999; 340: 1623-9.
34. The CAPTURE Investigators. Randomised placebo-controlled trial of abciximab before and during coronary intervention in refractory unstable angina: the CAPTURE Study. *Lancet* 1997; 349: 1429-35.
35. Mintz GS, Pichard AD, Kovach JA, Kent KM, Satler LF, Javier SP, Popma JJ, Leon MB. Impact of preintervention intravascular ultrasound imaging on transcatheter treatment strategies in coronary artery disease. *Am J Cardiol* 1994; 73: 423-30.