

# European Association of NeuroOncology Magazine

Neurology · Neurosurgery · Medical Oncology · Radiotherapy · Paediatric Neuro-  
oncology · Neuropathology · Neuroradiology · Neuroimaging · Nursing · Patient Issues

**Paraneoplastic Encephalitis  
Myelitis, and Posterior Column  
Degeneration in a Patient with  
Breast Cancer**

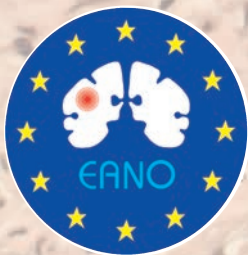Calabek B, Lindner K, Grisold W

*European Association of  
NeuroOncology Magazine 2012; 2 (2)  
93-94*

Homepage:

[www.kup.at/  
journals/eano/index.html](http://www.kup.at/journals/eano/index.html)

**Online Database Featuring  
Author, Key Word and  
Full-Text Search**



THE EUROPEAN ASSOCIATION OF  
NEUROONCOLOGY

Member of the



# Paraneoplastic Encephalitis, Myelitis, and Posterior Column Degeneration in a Patient with Breast Cancer

Bernadette Calabek, Klaus Lindner, Wolfgang Grisold

Department of Neurology, Kaiser-Franz-Josef-Spital, and Ludwig Boltzmann Institute of Neurooncology, Vienna, Austria

## ■ Introduction

Paraneoplastic neurological syndromes (PNS) are rare and have been divided into “classical” and “probable syndromes” according to clinical manifestations and antibody profile. Many PNS are associated with onconeural antibodies, but failure to detect these antibodies does not exclude the diagnosis. Paraneoplastic myelopathies often remain unrecognized and are usually associated with multifocal neurologic involvement. Prognosis and treatment are not well-defined. We report on a patient presenting with a severe affection of the spinal cord in context with a PNS.

## ■ Case Report

A 40-year-old woman had been suffering from vertigo and blurred vision for 2 months. Due to progression of the symptoms and ataxic gait, she was admitted to our department. She presented with rotatory nystagmus, diplopia as well as ataxia of the trunk and lower limbs. MRI of the brain was normal, MRI of the spine revealed a myelopathy of the cervical spinal cord. CSF was pleocytotic with 30 cells and oligoclonal bands were positive. Onconeural antibodies and surface antibodies for PNS were negative. High-dose corticosteroids led to minimal and short-lasting improvement. Neuromyelitis optica, sarcoidosis, or a rheumatic aetiology could be ruled out. The symptoms worsened, apallesthesia of the lower extremities suggested a posterior column lesion, which could be demonstrated in the MRI of the cervical spinal cord (Figures 1 and 2).

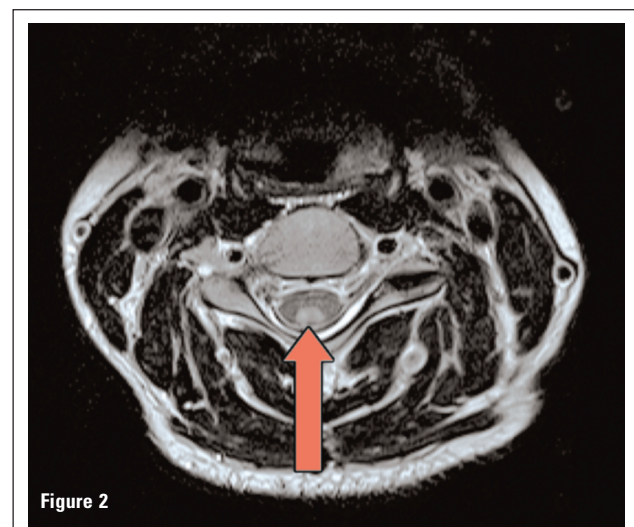
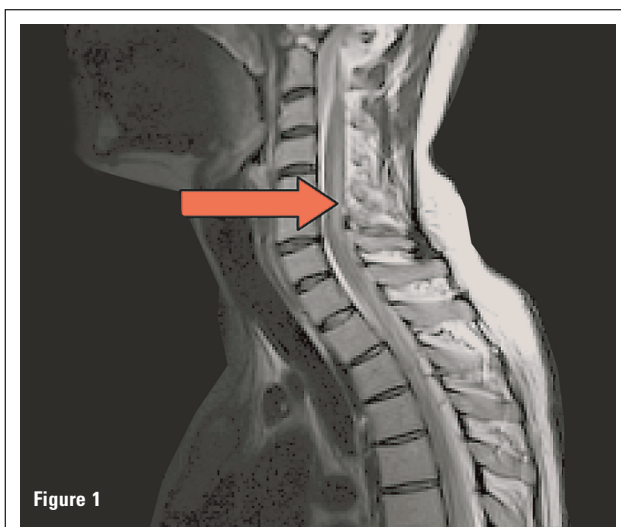
Due to ataxia of the trunk and lower extremities the patient was confined to a wheelchair. Finally, a CT scan of the thorax showed an enlarged lymph node in the axilla and biopsy revealed ectopic breast cancer (Her2-neu-protein-negative). A PET scan did not reveal any signs of cancer or metastases, several examinations of the breasts remained unremarkable.

## ■ Follow-Up

The patient received chemotherapy (doxorubicin and cyclophosphamide) for 6 months. Neurological symptoms did not remit and series with immunoglobulins (IvIG, 0.4 g/kg body weight) had no effect. The patient was discharged and has remained unchanged concerning neurological symptoms. She is severely disabled and still confined to the wheelchair.

## ■ Comment

The patient presented with an encephalitic-like onset with nystagmus, diplopia, and myelopathy resulting in apallesthesia. Due to the clinical features and positive oligoclonal bands a severe course of multiple sclerosis was considered. But the pattern of spinal cord alteration and normal findings in the cranial MRI suggested an alternative diagnosis. The newly discovered breast cancer, the oligoclonal bands, and CSF pleocytosis suggest a paraneoplastic origin. The involvement of posterior columns (Figures 1 and 2) is a new observation. Myelopathy is usually part of an encephalomyelitis as described in this case. The prognosis and response to treatment



Figures 1 and 2. T2-weighted MRI of the spinal cord: longitudinally symmetric extensive signal abnormalities of the posterior columns.



are not well-defined. The most common cancers associated with paraneoplastic myelopathy are cancers of the breast and lung. According to a recent review [1], paraneoplastic myelopathy results in severe disability and only a minority of patients improve with treatment. The rarity of paraneoplastic syndromes, in particular, paraneoplastic myelopathies, limits evidence of treatment, so knowledge about therapy relies on case reports and expert opinions. This case study could demonstrate MRI changes impressively. Symmetric, longitudinally extensive tract or grey matter alterations are characteristic for paraneoplastic myelopathy.

The classification of this PNS is difficult as the transient encephalitic symptoms, in association with focal myelopathy (posterior column), have neither been observed in the definite PNS [2] nor in association with the recently observed surface antibodies. Graus et al established criteria for definite or possible PNS. According to these criteria, our case has to be classified as possible PNS. The presence of the tumour and neurological symptoms but absent onconeural antibodies and lack of improvement after tumour therapy leads to the classification of a possible PNS.

**References:**

1. Flanagan EP, McKeon A, Lennon VA, et al. Paraneoplastic isolated myelopathy, clinical course and neuroimaging clues. *Neurology* 2011; 76: 2089–95.
2. Graus F, Delattre JY, Antoine JC, et al. Recommended diagnostic criteria for paraneoplastic neurological syndromes. *J Neurol Neurosurg Psychiatry* 2004; 75: 1135–40.

**Further Reading:**

Graber JJ, Nolan CP. Myelopathies in patients with cancer. *Arch Neurol* 2010; 67: 298–304.

Giometto B, Grisold W, Vitaliani R, et al. Paraneoplastic neurologic syndrome in the PNS Euronetwork Database. *Arch Neurol* 2010; 67: 330–5.

Vincent A, Bien CG, Irani SR, et al. Autoantibodies associated with diseases of the CNS: new developments and future challenges. *Lancet Neurol* 2011; 10: 759–72.

**Correspondence to:**

*Bernadette Calabek, MD*  
*Department of Neurology*  
*Kaiser-Franz-Josef-Spital, SMZ Süd*  
*Kundratstraße 3*  
*1100 Vienna*  
*Austria*  
*e-mail: bernadette.calabek@wienkav.at*