

Journal of Clinical and Basic Cardiology

An Independent International Scientific Journal



Journal of Clinical and Basic Cardiology 2000; 3 (2), 141-142

PRO: Stunning and hibernation: two faces of the same disease

Heyndrickx GR

Homepage:

www.kup.at/jcbc

**Online Data Base Search
for Authors and Keywords**

PRO: Stunning and Hibernation: Two Faces of the Same Disease?

G. R. Heyndrickx

The experimental observation that the myocardium, rendered ischaemic for a short period of time, displays a prolonged but reversible dysfunction – subsequently referred to as stunned myocardium – was described 10 years before the entity of hibernating myocardium – a condition of chronic regional left ventricular dysfunction in the presence of coronary obstructive lesions yet amenable to recover contractile force upon revascularization – was brought to the attention of clinicians. These two conditions have lived a life of their own until recent experimental as well as clinical evidence have come to view hibernation more as a result of repetitive episodes of stunning rather than an adaptive response to decreased perfusion. Hibernating myocardium should be considered as a degenerative condition where early revascularization may be of benefit by normalizing the coronary flow reserve, thereby eliminating the toxic ischaemia – reperfusion cycles. *J Clin Basic Cardiol* 2000; 3: 141–2.

Key words: stunning, hibernation, coronary flow reserve, repetitive ischaemia

Scanning the literature for chronic left ventricular dysfunction, the reader is puzzled by the fact that stunning and hibernation are often used alternately to address the issue of viability of chronic dysfunctioning myocardial segments in patients with ischaemic heart disease and therefore intrigued whether these two entities might represent two faces of the same disease. Is the currently available knowledge able to answer this question? In order to do so it is important to agree on a clear definition of stunning and hibernation.

Myocardial stunning is a temporary condition, a relatively short period (days, weeks) of postischaemic left ventricular dysfunction following a short episode of profound ischaemia [1]. The delay in recovery of the contractile deficit is not related in any way to residual regional hypoperfusion or irreversible cellular damage, but rather a consequence of a slow repair process of the minimal damage inflicted to the contractile proteins during the ischaemic episode. It is now well accepted that free radical production and intracellular calcium overload occurring typically at the time of reperfusion are to be blamed for this cellular damage [2, 3]. This phenomenon, first described in a controlled experimental setting was found to occur clinically as frequently as ischaemia itself in many patients with various ischaemic syndromes [4].

Hibernating myocardium, a clinical concept popularized by Rahimtoola, describes a more chronic (months, years) and supposedly stable condition of regional segmental dysfunction in patients with documented coronary obstructive lesions, in which revascularization procedures (CABG or PTCA) result more often in a partial rather than complete functional recovery [5]. In contrast to myocardial stunning where no histopathological abnormalities at the cellular level are demonstrable, biopsies of hibernating segments taken at the time of surgery have revealed marked structural alterations including substantial loss of myofibrillar content, cellular swelling and increased glycogen content [6]. Despite these alterations the dysfunctioning segments retain some contractile reserve when stimulated with inotropic agents. This characteristic of hibernating myocardium is used to advantage for diagnostic purposes.

Pathophysiology

The underlying pathophysiologic mechanisms as well as the sequence of events leading to hibernating myocytes are still controversial. Two major hypotheses are fighting for

recognition: the original hypothesis, proposed by Rahimtoola, suggests that hibernation results from an active down regulation of the metabolic and contractile functions triggered by hypoxia [5]. These adaptive processes are thought to involve molecular mechanisms at the cellular level. Through these phenotypic changes myocytes become able to hibernate, escaping the lethal evolution towards cell death. In other words, a chronic reduction in coronary perfusion elicits a matched reduction in contractile function, ie, a perfusion-contraction match, for as long as the hypoperfusion persists: the 'smart heart' so to speak [7]. Although the fundamental observation that some ischaemic markers, such as lactate production, loss of ATP stores and creatine phosphate, tend to normalize during short term ongoing ischaemia is taken by some as proof of concept, a definite confirmation that a similar process also underlies the long term adaptation to chronic ischaemia is still lacking [7]. The proponents of this hypothesis are also confronted with the facts that ischaemia of much longer duration (> 24 hours) results almost always in patchy necrosis.

Critics of this latter view, strengthened by the lack of hard data to support such a long term down regulatory process, have proposed a different mechanism, ie, hibernation occurs as a consequence of multiple and repetitive episodes of ischaemia and reperfusion, inducing each time a period of stunning until the frequency and intensity of the injury-repair cycles outrun the capabilities of the myocardium to preserve its integrity. With time this situation will lead to the observed degenerative changes as seen in biopsies taken from patients with chronic dysfunctioning segments [8]. Their case is built on quantitative coronary flow measurements using positron emission tomography in patients presenting with severe chronic regional dysfunction in an area subtended by an occluded coronary artery and yet with no sign of myocardial infarction or ongoing ischaemia. These studies have confirmed that resting coronary perfusion may vary from normal to modestly reduced and when reduced, the reduction is always well out of proportion to the reduction in segmental function reflecting a clear perfusion-contraction mismatch. But more importantly, all these patients are characterized by a severely reduced coronary flow reserve. In addition, myocardial biopsies from patients undergoing surgical revascularization revealed all characteristic histological abnormalities [9].

The gap between these two hypotheses put forward to explain the process of hibernation has been somewhat nar-

rowed in recent years since both schools now agree to the fact that, regardless of the issue of basal resting flow which may be normal, near normal or decreased, the coronary flow reserve is always severely reduced or even abolished.

It stands to reason that the presence of a severely reduced coronary flow reserve together with underlying viable myocardium must inevitably result periodically in an imbalance between the available oxygen supply and the oxygen consumption whenever the metabolic demands of the myocardium are increased such as during physical activity or excitement. This situation is therefore prone to repetitive episodes of temporary ischaemia each time the metabolic load is increased resulting in repetitive stunning leading to cumulative contractile dysfunction.

Repetitive stunning: a link between stunning and hibernation. Is there evidence for cumulative contractile dysfunction with repetitive stunning?

There is ample evidence in acute animal models that repeated episodes of intense ischaemia induced by short occlusions (5 min) interspaced with 10 min of reperfusion result in cumulative contractile dysfunction. It is now generally accepted that the repetition of bursts of free radical production with each cycle of ischaemia-reperfusion results in a cumulative release of PBN adducts. Despite the fact that the amount of free radicals, measured by the PBN adducts, decreases after the first occlusion, reflecting preconditioning, each subsequent cycle of occlusion-reperfusion is still able to produce free radical products, albeit to a lesser degree [2]. This cumulative toxic effect of free radicals is translated into a cumulative contractile deficit. A clinical corollary of cumulative myocardial dysfunction after repeated episodes of ischaemia was observed by Rinaldi et al. in a group of patients with exercise induced ischaemia when subjected to repetitive stress tests [10].

Experimental confirmation that long term repetitive stunning can indeed induce permanent chronic dysfunction without infarction came recently from several laboratories. Different animal models were used to produce chronic segmental dysfunction to mimic the clinical setting of hibernation [11–14]. Instrumentation with ameroid occluders or fixed coronary artery stenoses produces a slow (2–3 weeks) but progressive reduction in coronary vessel diameter leading to flow reduction unless compensatory collaterals are recruited. If collateral vessels develop at the right pace and to the right extent, as can be seen in the dog model, basal perfusion as well as a significant portion of the coronary vascular reserve remain intact, in which case metabolic stress should be adequately met with increased flow. In case of immature collateral development, typically seen in the pig model, the entire process of vessel occlusion is characterized by a progressive reduction in coronary flow reserve.

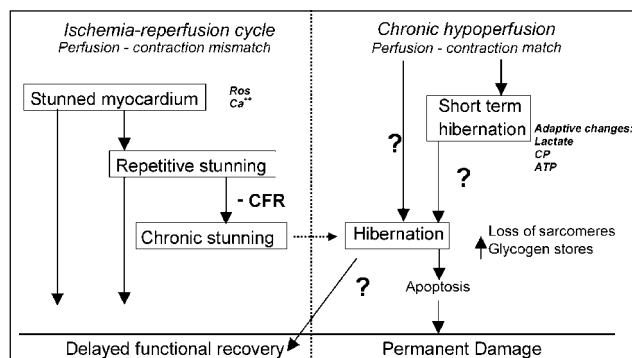


Figure 1. Chronic left ventricular dysfunction: Repetitive stunning versus hibernation

Thus, preservation of normal basal flow occurs at the expense of a decrease in coronary vascular reserve. During this entire period of reduced flow reserve episodes, of high metabolic demand-low flow ischaemia were documented during daily activities of the animals which resulted in progressive severe loss in regional contractile function without evidence for cell necrosis [11]. Biopsies taken from such segments revealed similar cellular abnormalities as described in humans. An intriguing observation is the presence of apoptotic cell death in such biopsies suggesting that hibernating myocardium is a continuously evolving process leading to progressive loss in the contractile machinery [15]. Recent long term experiments have shown that during the development of segmental dysfunction, basal coronary perfusion remains normal during the first weeks of monitoring, but then decreases when the monitoring period was extended over several months [14, 16]. This observation may explain why chronic dysfunctioning segments in patients display a wide range of resting flows varying from normal to reduced considering the different time intervals when patients are studied.

Conclusion

While stunning and hibernation were initially described as separate entities, the accumulated evidence leads us to think that perhaps the two syndromes are closely linked. Repetitive stunning leads to chronic stunning, a state of prolonged contractile dysfunction. Non-contractile myocytes then acquire progressive cellular abnormalities in part due to a process of mechanical unloading and may explain, on an autoregulatory basis, a decrease in regional perfusion, all features of hibernation (Fig. 1). Thus, hibernation should be viewed as an end stage condition of repetitive stunning, less stable and less reversible than initially proposed, needing an aggressive therapeutic approach.

References

- Heyndrickx GR, Millard RW, McRitchie RJ, Maroko PR, Vatner SF. Regional myocardial functional and electrophysiological alterations after brief coronary artery occlusion in conscious dogs. *J Clin Invest* 1975; 56: 978–85.
- Bolli R, Marban E. Molecular and cellular mechanisms of myocardial stunning. *Physiol Rev* 1999; 79: 609–34.
- Bolli R. Mechanism of myocardial “stunning”. *Circulation* 1990; 82: 723–38.
- Vatner SF, Heyndrickx GR. Ubiquity of myocardial stunning. *Basic Res Cardiol* 1995; 90: 253–6.
- Rahimtoola SH. The hibernating myocardium. *Am Heart J* 1989; 117: 211–21.
- Flameng W, Suy R, Schwarz F, Borgers M, Piessens J, Thone F, Van Ermen H, De Geest H. Ultrastructural correlates of left ventricular contraction abnormalities in patients with chronic ischemic heart disease: determinants of reversible segmental asynergy postrevascularization surgery. *Am Heart J* 1981; 102: 846–57.
- Heusch G. Hibernating myocardium. *Physiol Rev* 1998; 78: 1055–85.
- Vanoverschelde JL, Wijns W, Degré C, Essamri B, Heyndrickx GR, Borgers M, Bol A, Melin JA. Mechanisms of chronic regional postischemic dysfunction in humans. New insights from the study of noninfarcted collateral-dependent myocardium. *Circulation* 1993; 87: 1513–23.
- Wijns W, Vatner SF, Camici PG. Hibernating myocardium. *N Engl J Med* 1998; 339: 173–81.
- Rinaldi CA, Masani ND, Linka AZ, Hall RJ. Effect of repetitive episodes of exercise induced myocardial ischemia on left ventricular function in patients with chronic stable angina: evidence for cumulative stunning or ischemic preconditioning? *Heart* 1999; 81: 404–11.
- Shen YT, Vatner SF. Mechanism of impaired myocardial function during progressive coronary stenosis in conscious dogs. Hibernating versus stunning? *Cir Res* 1995; 76: 479–88.
- Canty JM, Fallavollita JA. Resting myocardial flow in hibernating myocardium: validating animal models of human pathophysiology. *Am J Physiol* 1999; 276: H417–H422.
- Firoozan S, Wei K, Linka A, Skyba D, Goodman C, Kaul S. A canine model of chronic ischemic cardiomyopathy: characterization of regional flow-function relations. *Am J Physiol* 1999; 276: H446–H455.
- Shivalkar B, Flameng W, Szilard M, Pislaru S, Borgers M, Vanhaecke J. Repeated stunning precedes myocardial hibernation in progressive multiple coronary artery obstruction. *J Am Coll Cardiol* 1999; 34: 2126–36.
- Lim H, Fallavollita JA, Hard R, Kerr CW, Canty JM. Profound apoptosis-mediated regional myocyte loss and compensatory hypertrophy in pigs with hibernating myocardium. *Circulation* 1999; 100: 2380–6.
- Fallavollita JA, Canty JM. Differential ¹⁸F-2-deoxyglucose uptake in viable dysfunctional myocardium with normal resting perfusion. *Circulation* 1999; 99: 2798–2805.

Mitteilungen aus der Redaktion

Besuchen Sie unsere zeitschriftenübergreifende Datenbank

☒ [Bilddatenbank](#)

☒ [Artikeldatenbank](#)

☒ [Fallberichte](#)

e-Journal-Abo

Beziehen Sie die elektronischen Ausgaben dieser Zeitschrift hier.

Die Lieferung umfasst 4–5 Ausgaben pro Jahr zzgl. allfälliger Sonderhefte.

Unsere e-Journale stehen als PDF-Datei zur Verfügung und sind auf den meisten der marktüblichen e-Book-Readern, Tablets sowie auf iPad funktionsfähig.

☒ [Bestellung e-Journal-Abo](#)

Haftungsausschluss

Die in unseren Webseiten publizierten Informationen richten sich **ausschließlich an geprüfte und autorisierte medizinische Berufsgruppen** und entbinden nicht von der ärztlichen Sorgfaltspflicht sowie von einer ausführlichen Patientenaufklärung über therapeutische Optionen und deren Wirkungen bzw. Nebenwirkungen. Die entsprechenden Angaben werden von den Autoren mit der größten Sorgfalt recherchiert und zusammengestellt. Die angegebenen Dosierungen sind im Einzelfall anhand der Fachinformationen zu überprüfen. Weder die Autoren, noch die tragenden Gesellschaften noch der Verlag übernehmen irgendwelche Haftungsansprüche.

Bitte beachten Sie auch diese Seiten:

[Impressum](#)

[Disclaimers & Copyright](#)

[Datenschutzerklärung](#)