

European Association of NeuroOncology Magazine

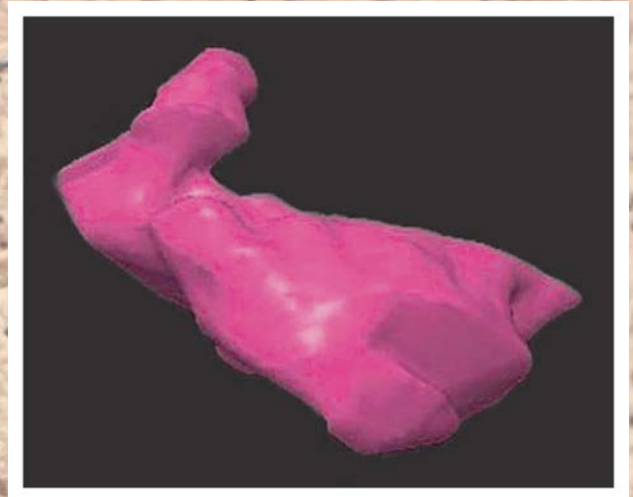
Neurology · Neurosurgery · Medical Oncology · Radiotherapy · Paediatric Neuro-
oncology · Neuropathology · Neuroradiology · Neuroimaging · Nursing · Patient Issues

Hotspots in Neuro-Oncology

Weller M

*European Association of
NeuroOncology Magazine 2013; 3 (1)*

37



Homepage:

[www.kup.at/
journals/eano/index.html](http://www.kup.at/journals/eano/index.html)

Online Database Featuring
Author, Key Word and
Full-Text Search



THE EUROPEAN ASSOCIATION OF
NEUROONCOLOGY

Member of the



Hotspots in Neuro-Oncology

Michael Weller

From the Department of Neurology, University Hospital Zurich, Switzerland

■ Radiotherapy and Temozolomide in Anaplastic Astrocytoma: A Retrospective Multicenter Study by the Central Nervous System Study Group of AIRO (Italian Association of Radiation Oncology)

Scoccianti S, et al. Neuro Oncol 2012; 14: 798–807.

Too many neuro-oncologists change their personal standards of care over time without adequate support from clinical trials. A classical example for this observation is the increasing use of temozolomide in addition to radiotherapy in the first-line treatment of anaplastic astrocytoma. The largest recent trial in that patient population, the German NOA-04 trial, had compared radiotherapy alone with alkylating agent chemotherapy alone and found no difference between these 2 treatments for any endpoint. In the June issue of *Neuro-Oncology*, an Italian consortium reported a retrospective study of 295 patients with newly diagnosed anaplastic astrocytoma treated from 2002–2007. All patients had received radiotherapy, 67 % received postoperative temozolomide. The majority had both concomitant and adjuvant temozolomide. The increasing use of temozolomide over the time frame covered did not produce an improvement in survival. This interesting analysis emphasizes the need to base changes in standards of care on adequate randomized trials. At present, the ongoing CATNON trial is closest to answering the question of whether anaplastic astrocytoma patients should be treated with combined modality treatment upfront.

■ Clinical and Molecular Characteristics of Congenital Glioblastoma

Macy ME, et al. Neuro Oncol 2012; 14: 931–41.

In the July issue, a rare variant of glioblastoma, congenital glioblastoma, was studied and reviewed. The authors reported an analysis of 5 such patients, 1 died at surgery, the other 4 patients had adequate tumour control with a median progression-free survival of 36 months (range: 30–110 months) with chemotherapy alone. There were no characteristic patterns on molecular characterization using Affymetrix microarrays and exhibited expression profiles related both to paediatric and adult glioblastoma.

■ Incidence, Treatment and Survival of Patients with Craniopharyngioma in the Surveillance, Epidemiology and End Results Program

Zacharia BE, et al. Neuro Oncol 2012; 14: 1070–8.

Craniopharyngioma is a rare brain tumour which may occur in almost any age group and where treatment decisions are

often controversial, specifically regarding the extent of resection and the role and timing of radiotherapy. In the August issue, Zacharia et al presented an overview of 644 patients with craniopharyngioma diagnosed between 2004 and 2008 with data derived from the Surveillance, Epidemiology and End Results program (SEER) database. One- and 3-year survival rates were 92 % and 86 %. On multivariate modelling, younger age, smaller tumours, subtotal resection, and administration of radiotherapy were favourable prognostic factors, whereas black race was associated with less favourable outcome. Altogether, this publication provides a contemporary overview on the incidence, clinical presentation, and current patterns of care for this rare brain tumour which may serve well for the design and conduct of future clinical trials in this disease.

■ Phase II Trial of Lapatinib in Adult and Pediatric Patients with Neurofibromatosis Type 2 and Progressive Vestibular Schwannomas

Karajannis MA, et al. Neuro Oncol 2012; 14: 1163–70.

Medical treatment options for patients with neurofibromatosis type 2 (NF2) and schwannomas progressing after surgery and radiotherapy are scarce. In the September issue, Karajannis et al reported the results of a single-institution phase-II study to assess the response of patients affected by these tumours to lapatinib, a reversible inhibitor of epidermal growth factor receptor and ErbB2. Response was defined as a > 15-% decrease in tumour volume. This endpoint was evaluable in 17 patients. Hearing performance was available as a secondary endpoint in 13 patients. Four of 17 available patients showed an objective response with a median time to response of 4.5 months. Four of 13 patients available for hearing had a response, too. Toxicity was in general minor and no modifications of the dose of 900 mg/m² twice daily (paediatric patients), respectively 1500 mg flat daily for adult patients were made. Overall, this study demonstrates some objective activity of lapatinib in NF2 patients with progressive vestibular schwannomas. While this efficacy is limited, it adds to the current repertoire of pharmacological agents with some benefit in these patients that are notoriously difficult to treat. Combinations of lapatinib with vascular endothelial growth factor antagonists seem to be the next step.

Correspondence to:

Michael Weller, MD

*Department of Neurology, University Hospital Zurich
Frauenklinikstrasse 26*

8091 Zurich, Switzerland

e-mail: michael.weller@usz.ch