

Journal of Clinical and Basic Cardiology

An Independent International Scientific Journal



Journal of Clinical and Basic Cardiology 2002; 5 (2), 199-200

Rupture of a Surgically Repaired Sinus of Valsalva Aneurysm

Raufi A, Khan IA, Nair VM, Rahmatullah SI, Rodriguez C
Sacchi TJ, Sahni G, Vasavada BC

Homepage:

www.kup.at/jcbc

**Online Data Base Search
for Authors and Keywords**

Rupture of a Surgically Repaired Sinus of Valsalva Aneurysm

A. Raufi¹, I. A. Khan², G. Sahni¹, S. I. Rahmatullah¹, V. M. Nair¹, C. Rodriguez¹, B. C. Vasavada¹, T. J. Sacchi¹

Congenital aneurysms of aortic sinuses of Valsalva are uncommon anomalies caused by congenital defects in a region between aortic media and aortic fibrous ring. They are thin walled, tubular outpouchings with an entirely intracardiac course, and have a tendency to rupture into cardiac chambers, mostly right-sided, resulting in formation of an aortocardiac fistula. Surgical repair is the treatment of choice. Although the surgical repair usually is successful with good short- and long-term prognosis, rupture of a repaired sinus of Valsalva aneurysm is still possible. Here reported is a 50-year-old patient who underwent surgical repair of a right sinus of Valsalva aneurysm, and one month later presented with complaints of shortness of breath, orthopnoea, paroxysmal nocturnal dyspnoea, and chest pain. He underwent transoesophageal echocardiography, aortography, and cardiac catheterization. These investigations demonstrated rupture of the previously repaired right sinus of Valsalva resulting in formation of a fistula between aorta and right atrium with a left to right shunt. He subsequently underwent a successful repair of the ruptured sinus of Valsalva and closure of aortoatrial fistula. *J Clin Basic Cardiol* 2002; 5: 199–200.

Key words: sinus of Valsalva aneurysm, rupture, aortocameral fistula, aortoatrial fistula, aortic disease, congenital heart disease, congestive heart failure, aortocardiac fistula, cardiac surgery

Although congenital aneurysms of sinuses of Valsalva are uncommon disorders, their rupture usually results in a rapid onset of heart failure and haemodynamic deterioration [1, 2]. The treatment of aneurysm of sinus of Valsalva is by surgical repair. Even though the surgical repair usually is successful with good short- and long-term prognosis, rupture of a repaired sinus of Valsalva aneurysm is still possible. Here presented is a case of rupture of a repaired sinus of Valsalva aneurysm.

Case Report

A 50 year old man was admitted with complaints of shortness of breath, orthopnoea, paroxysmal nocturnal dyspnoea, and chest pain of 3-week duration. One month prior to presentation, he had undergone surgical repair of right sinus of Valsalva

aneurysm. His cardiac examination was remarkable for sinus tachycardia and presence of a 3/6 continuous murmur, louder during systole at the left sternal border. The patient underwent transoesophageal echocardiography, which revealed ruptured right sinus of Valsalva, dilated right-sided cardiac chambers, and bicuspid aortic valve (Fig. 1). Color flow mapping revealed evidence of a high velocity shunt from aorta to right atrium. Aortography and cardiac catheterization were performed which demonstrated presence of a fistula from aorta to the right atrium with left to right shunt (Fig. 2). The coronary arteries were free of obstruction, and aortic valve was competent. Mean right atrial pressure was 25 mmHg, right ventricular pressure 65/15 mmHg, pulmonary arterial pressure 64/35 mmHg, and mean pulmonary capillary wedge pressure 30 mmHg. The oxygen saturation in superior vena cava was 55 % and that in right atrium 77 % with a step-up of 22 %. The pulmonary to systemic circulation ratio (qP/qS)

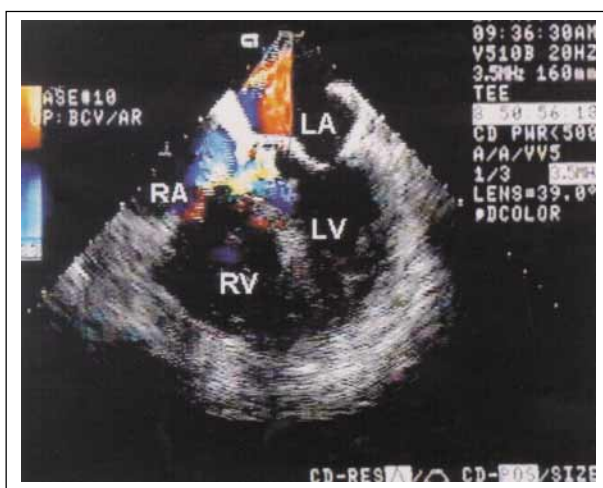

Figure 1. Transoesophageal echocardiography demonstrates dilated right atrium (RA) and right ventricle (RV) and a high velocity shunt from aorta to right atrium. LA = left atrium, LV = left ventricle

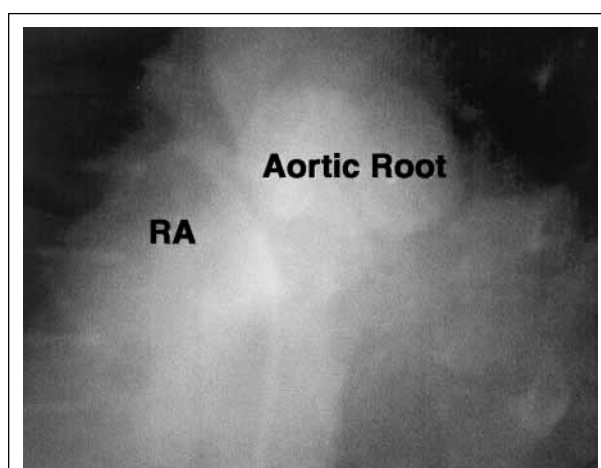


Figure 2. Aortogram demonstrates a communication between aorta and right atrium (RA)

Received June 15th, 2001; accepted September 4th, 2001.

From the ¹Division of Cardiology, Long Island College Hospital, Brooklyn, New York and the ²Creighton University School of Medicine, Omaha, Nebraska, USA

Correspondence to: Ijaz A. Khan, MD, Creighton University Cardiac Center, 3006 Webster Street, Omaha, NE 68131, USA;

e-mail: ikhan@cardiac.creighton.edu

was 1.46. The patient underwent a successful repair of the ruptured sinus of Valsalva with closure of the fistula and had an uneventful course. He was free of symptoms at 1-year follow-up.

Discussion

Congenital aneurysms of the sinuses of Valsalva are thin walled, tubular, narrow outpouchings arising almost always from the right sinus or the adjacent half of the non-coronary sinus. These aneurysms encompass an entirely intracardiac course, and have a tendency to rupture, chiefly into the right heart chambers, resulting in an aortocardiac fistula. Congenital aneurysms of sinuses of Valsalva are three times more common in males than in females and a substantial majority of ruptures occur around the age of 30 [1, 2]. The underlying lesion that predisposes to the development of aneurysm is thinning of the aortic sinus wall, as a result of congenital absence of normal elastic and muscular tissues, just above the aortic annulus at the point of leaflet hinge. As a result, the aortic media separates from aortic annulus and retracts upward. The part of sinus wall that lies between the aortic annulus and upward retracted media becomes aneurysmal with passage of time. The most common sites where these congenital defects occur are in the right (55 % to 81 %) and the non-coronary (11 %) sinuses; therefore, the rupture of sinus of Valsalva aneurysm typically creates aortic communication with right ventricle (63 %) or right atrium (32 %) [3, 4]. Other structures into which sinus of Valsalva aneurysms have ruptured include left atrium, left ventricle, superior vena cava, pericardium, thoracic wall, and pulmonary artery [4, 5]. In addition to the congenital defects, other reported causes of formation of sinus of Valsalva aneurysm include cystic medial necrosis, trauma, bacterial endocarditis, syphilis, tuberculosis, and Behcet's disease [6].

Formation of various aortocardiac fistulas is associated with development of typical flow patterns as a function of the pressure gradient between aorta and the specific cardiac chamber involved. Flow into the left ventricle is holodiastolic with the highest velocity in early diastole, flow into the right ventricle is primarily systolic with lower velocities during diastole and flow into either atrium is continuous with higher velocities during systole. It is important to delineate these fistulous tracts preoperatively because the choice of surgical approach for their repair depends on the chamber the aneurysm has ruptured into [7]. Similarly, it is also important to delineate the associated anomalies, which are common, and include bicuspid aortic valve, ventricular septal defect, and coarctation of aorta.

After rupture of a sinus of Valsalva aneurysm, cardiac failure develops relatively rapidly and becomes severe. Chest pain and dyspnoea may precede heart failure if rupture is abrupt, but the exact haemodynamic consequences depend on the size of the shunt, rapidity of onset, and the chamber into which rupture takes place [8]. Characteristically, the murmur of ruptured sinus of Valsalva is loud and continuous but best heard lower on the chest than the murmur of a patent ductus arteriosus. Electrocardiogram may show biventricular diastolic overload patterns. Two-dimensional and pulsed

Doppler echocardiographic studies may detect the walls of the aneurysm and disturbed flow patterns within the aneurysm or at the site of perforation [7]. Cardiac catheterization will confirm the level of the shunt. Aortography is necessary for confirmation of the diagnosis. In addition to acute heart failure, other complications reported with ruptured sinus of Valsalva aneurysm include bacterial endocarditis, cardiac conduction defects, cardiac tamponade, and myocardial ischaemia [9–12].

Because of the natural history of progressive deterioration in cardiac function in patients with untreated ruptured sinus of Valsalva aneurysm, all of these patients are treated surgically. The medical management is limited to treating heart failure and any coexistent arrhythmias or endocarditis, if present. At operation the aneurysm is closed and amputated, and the aortic wall is reunited with the heart, either by direct suture or by prosthesis [13]. The surgical treatment for ruptured sinus of Valsalva aneurysm is usually successful and carries good short- and long-term results but recurrence is possible because of suture or prosthesis dehiscence as well as persistence of the underlying congenital defects in aortic wall [14]. Therefore, close long-term follow-up for early detection of rupture of a repaired sinus of Valsalva aneurysm is crucial.

References

1. Bouteffeu JM, Moret PR, Hahn C, Hauf E. Aneurysms of the sinus of Valsalva; report of seven cases and review of the literature. *Am J Med* 1978; 65: 18–24.
2. Mayer ED, Ruffmann K, Saggau W, Butzmann B, Bernhardt-Mayer K, Schatton N, Schmitz W. Ruptured aneurysms of the sinus of Valsalva. *Ann Thorac Surg* 1986; 42: 81–5.
3. Katz ES, Cziner DG, Rosenzweig BP, Attubato M, Feit F, Kronzon I. Multifaceted echocardiographic approach to the diagnosis of a ruptured sinus of Valsalva aneurysm. *J Am Soc Echocardiogr* 1991; 4: 494–8.
4. Chow LC, Dittrich HC, Dembitsky WP, Nicod PH. Accurate localization of ruptured sinus of Valsalva aneurysm by real-time two-dimensional color flow imaging. *Chest* 1988; 94: 462–5.
5. Heilman KJ, Groves BM, Campbell D, Blount SG. Rupture of left sinus of Valsalva aneurysm into the pulmonary artery. *J Am Coll Cardiol* 1985; 5: 1005–7.
6. Shumacker HB. Aneurysms of aortic sinuses of Valsalva due to bacterial endocarditis with special reference to their operative management. *J Thorac Cardiovasc Surg* 1972; 63: 896–902.
7. Abdelkhirane C, Roudaut R, Dallochio M. Diagnosis of ruptured sinus of Valsalva aneurysms: Potential value of transesophageal echocardiography. *Echocardiography* 1990; 7: 555–60.
8. Peters P, Juziuk E, Gunther S. Doppler color flow mapping detection of ruptured sinus of Valsalva aneurysm. *J Am Soc Echocardiogr* 1989; 2: 195–7.
9. Dominguez JC, Sanchez MA, Moreno AR. Infective endocarditis as a complication of a ruptured aneurysm of the sinus of Valsalva. *Heart* 1999; 82: 278.
10. Onat A, Ersanli O, Kanuni A, Aykan TB. Congenital aortic sinus aneurysms with particular reference to dissection of the interventricular septum. *Am Heart J* 1966; 72: 158–64.
11. Munk MD, Gatzoulis MA, King DE, Webb GD. Cardiac tamponade and death from intrapericardial rupture of sinus of Valsalva aneurysm. *Eur J Cardiothorac Surg* 1999; 15: 100–2.
12. Takahara Y, Sudo Y, Sunazawa T, Nakajima N. Aneurysm of the left sinus of Valsalva producing aortic valve regurgitation and myocardial ischemia. *Ann Thorac Surg* 1998; 65: 535–7.
13. Barragry TP, Ring WS, Moller JH, Lillehei CW. 15- to 30-year follow up of patients undergoing repair of ruptured congenital aneurysms of the sinus of Valsalva. *Ann Thorac Surg* 1988; 46: 515–9.
14. Au WK, Chiu SW, Mok CK, Lee WT, Cheung D, He GW. Repair of ruptured sinus of Valsalva aneurysm: determinants of long-term survival. *Ann Thorac Surg* 1998; 66: 1604–10.

No financial support was received for this paper.

Mitteilungen aus der Redaktion

Besuchen Sie unsere zeitschriftenübergreifende Datenbank

☒ [Bilddatenbank](#)

☒ [Artikeldatenbank](#)

☒ [Fallberichte](#)

e-Journal-Abo

Beziehen Sie die elektronischen Ausgaben dieser Zeitschrift hier.

Die Lieferung umfasst 4–5 Ausgaben pro Jahr zzgl. allfälliger Sonderhefte.

Unsere e-Journale stehen als PDF-Datei zur Verfügung und sind auf den meisten der marktüblichen e-Book-Readern, Tablets sowie auf iPad funktionsfähig.

☒ [Bestellung e-Journal-Abo](#)

Haftungsausschluss

Die in unseren Webseiten publizierten Informationen richten sich **ausschließlich an geprüfte und autorisierte medizinische Berufsgruppen** und entbinden nicht von der ärztlichen Sorgfaltspflicht sowie von einer ausführlichen Patientenaufklärung über therapeutische Optionen und deren Wirkungen bzw. Nebenwirkungen. Die entsprechenden Angaben werden von den Autoren mit der größten Sorgfalt recherchiert und zusammengestellt. Die angegebenen Dosierungen sind im Einzelfall anhand der Fachinformationen zu überprüfen. Weder die Autoren, noch die tragenden Gesellschaften noch der Verlag übernehmen irgendwelche Haftungsansprüche.

Bitte beachten Sie auch diese Seiten:

[Impressum](#)

[Disclaimers & Copyright](#)

[Datenschutzerklärung](#)