

Journal für
Mineralstoffwechsel
Zeitschrift für Knochen- und Gelenkserkrankungen
Orthopädie • Osteologie • Rheumatologie

**Radiofrequency Kyphoplasty for the
Treatment of Osteoporotic and
Neoplastic Vertebral Body Fractures
- Preliminary Experience and
Clinical Results after 6 Months**

Elgeti F, Gebauer B

*Journal für Mineralstoffwechsel &
Muskuloskelettale Erkrankungen
2011; 18 (Supplementum 1), 5-9*

Homepage:

**[www.kup.at/
mineralstoffwechsel](http://www.kup.at/mineralstoffwechsel)**

**Online-Datenbank mit
Autoren- und Stichwortsuche**

Member of the



Indexed in SCOPUS/EMBASE/Excerpta Medica
www.kup.at/mineralstoffwechsel



Offizielles Organ der
Österreichischen Gesellschaft
zur Erforschung des Knochens
und Mineralstoffwechsels



Österreichische Gesellschaft
für Orthopädie und
Orthopädische Chirurgie



Österreichische
Gesellschaft
für Rheumatologie

Krause & Pachernegg GmbH · VERLAG für MEDIZIN und WIRTSCHAFT · A-3003 Gablitz

P.b.b. GZ02Z031108M, Verlagspostamt: 3002 Purkersdorf, Erscheinungsort: 3003 Gablitz

Erschaffen Sie sich Ihre ertragreiche grüne Oase in Ihrem Zuhause oder in Ihrer Praxis

Mehr als nur eine Dekoration:

- Sie wollen das Besondere?
- Sie möchten Ihre eigenen Salate, Kräuter und auch Ihr Gemüse ernten?
- Frisch, reif, ungespritzt und voller Geschmack?
- Ohne Vorkenntnisse und ganz ohne grünen Daumen?

Dann sind Sie hier richtig



Radiofrequency Kyphoplasty for the Treatment of Osteoporotic and Neoplastic Vertebral Body Fractures

Preliminary Experience and Clinical Results after 6 Months

F. Elgeti, B. Gebauer

Abstract: Vertebroplasty and conventional kyphoplasty using a balloon or a stent are established methods for the treatment of painful osteoporotic or neoplastic vertebral compression fractures that are resistant to conservative medical treatment. Radiofrequency (RF) kyphoplasty with ultra-high viscosity cement is an innovative method. It permits safe and effective treatment of painful osteoporotic and neoplastic vertebral compression fractures while preserving non-compromised cancellous bone. **J Miner Stoffwechs 2011; 18 (Supplement 1): 5–9.**

■ Introduction

Radiofrequency kyphoplasty using the DFine-StabiliT® Vertebral Augmentation System is an evolutionary minimally-invasive procedure for the treatment of osteoporotic vertebral body fractures. Polymethylmethacrylate (PMMA) cement-based vertebroplasty and conventional balloon kyphoplasty were developed in the 1980s [1] and 1990s [2]. Since this time, they have been established and repeatedly validated as suitable procedures to achieve effective pain relief in patients with osteoporotic or neoplastic vertebral body fractures [3]. The low rate of symptomatic complications has definitely contributed to the widespread acceptance of the procedures [4]. However, rare symptomatic complications, such as transient radiculopathies, are due to frequent and uncontrolled cement leakage and cement embolism (up to 23 %), which may be regarded as system-immanent phenomena [5]. These incidents are caused by the low viscosity of the cement and, in rare cases, culminate in fatal paraplegia as described in a few case reports [6]. The incidents have also been associated with pulmonary, cardiac or paradoxical cerebral cement embolization [5, 7–9]. Therefore, cement leakage and avoidance strategies such as the use of venography [10] and a wide range of procedures including balloon kyphoplasty have long been the focus of technical discussion and development. The use of ultra-high viscosity cement and a dedicated application system for radiofrequency kyphoplasty promises better control of the cement during application and thus avoids uncontrolled leakage or embolization. In the following article we describe our preliminary experience with the system as well as the technical and clinical success achieved during the intervention and during follow-up.

The indication for vertebroplasty or kyphoplasty is established according to the guidelines and by interdisciplinary consensus: in cases of symptomatic therapy-refractory vertebral body frac-

tures resistant to conservative drug treatment, or those of traumatic or neoplastic origin [11]. Conservative treatment should have been attempted for at least three weeks [12]. Unstable fractures should be treated as early as possible. The indications and the selection of patients for different cement compositions (such as PMMA, calcium phosphate etc.) have not yet been clearly defined. However, for purely PMMA-based cements such as DFine-StabiliT® ER² Bone Cement, the lower age limit of 60 years should be respected because we still lack long-term results for osteoporotic vertebral body fractures. However, this age limit usually does not apply to oncological patients.

■ Patients and Method

We retrospectively investigated patients who had been treated with radiofrequency kyphoplasty in the first half of 2009. The underlying disease, age and grading of the fracture, the type of access (unipedicular/bipedicular), the volume of cement, peri-interventional complications (symptomatic spinal or foraminal cement leakage, pulmonary cement embolism, hemorrhage) and subsequent fractures were registered. Pain scores on the visual analog scale (VAS) and the Oswestry disability index (ODI) were determined pre-interventionally, post-interventionally (maximum 7 days), and 6 months after the intervention. VAS and ODI were compared to pre-interventional findings using the Wilcoxon rank sum test.

Inclusion and Exclusion Criteria

We retrospectively evaluated patients who had undergone treatment with radiofrequency kyphoplasty in the first half of 2009. Inclusion and exclusion criteria were symptomatic thoracic or lumbar type A fracture and no previous surgery in the spine during the preceding 12 months.

Clinical Investigation and Follow-up

The clinical examination consisted of a neurological examination to exclude fracture-associated neurological deficits or radicular symptoms. Pain scores were determined semi-quantitatively on a VAS (0–10). The ODI was determined in German [13]. On the ODI 0–20 % signified minimal, 21–40 % moderate, 41–60 % marked and 61–80 % very marked limitations,

From the Department of Diagnostic and Interventional Radiology at Charité Campus Virchow-Klinikum in Berlin, Germany

Correspondence address: Dr. med. Florian Elgeti, Klinik für Strahlenheilkunde, Charité Universitätsmedizin Berlin, Campus Virchow-Klinikum, Augustenburgerplatz 1, D-13353 Berlin; E-Mail: florian.elgeti@charite.de

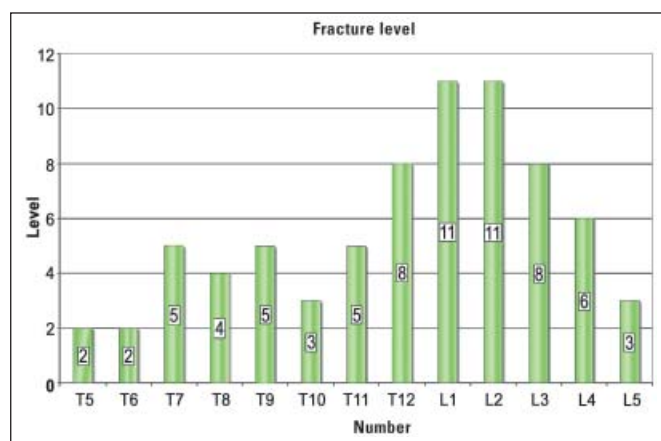


Figure 1: Treated segment levels/numbers

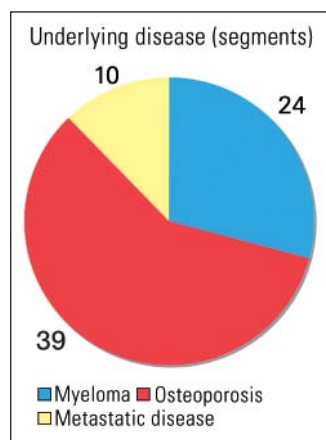


Figure 2: Underlying diseases in the treated patients/treated segments

while patients with a score of 81–100 % were bed-ridden. Scores were determined pre-interventionally, post-interventionally at the time of discharge from the hospital (at the latest after one week), and after 6 months. Comparisons of the course of VAS and ODI scores over time as well as comparisons with pre-interventional values were performed using the Wilcoxon rank sum test.

Imaging Procedures

The imaging procedures for pre-interventional diagnosis consisted of conventional X-rays of the affected portion of the spine in two planes; these should be preferably obtained with the patient standing upright and, if necessary, complemented by functional images. According to Genant et al's [14] semiquantitative method, an osteoporotic fracture between the fourth thoracic and fourth lumbar vertebra is defined as a > 20 % deformation of vertebral height over an area comprising at least 10 to 20 %. A height reduction of 20–25 % is defined as Grade 1, 25–40 % as Grade 2, and > 40 % as a Grade 3 fracture. Alterations in the endplates and in morphology compared to the adjacent vertebrae are included in the assessment. MRT diagnosis of the spine (T1-weighted, T2-weighted, STIR, for oncological patients with the use of contrast medium if necessary) was performed routinely, provided the patient had no contraindications for the procedure. We also performed a targeted spinal CT of the segments to be augmented, a chest X-ray pre-interventionally for assessment of the patient's cardiopulmonary status, and post-interventionally to exclude relevant cement embolism.

Intervention

The treatment was conducted at our department during a brief in-hospital stay. The actual procedure was performed in a biplanar X-ray fluoroscopy system (Neurostar, Siemens, Erlangen). Alternatively, in some cases it was conducted during combined CT fluoroscopy and C-arm fluoroscopy. We per-

formed all interventions with the patient in prone position, under sterile conditions, conscious sedation, and continuous monitoring of the patient.

The type of access (unipedicular/bipedicular), cement volume, peri-interventional complications (symptomatic spinal or foraminal cement leakage, pulmonary cement embolism, hemorrhage, infection) were registered.

Results

Thirty-five patients (18 ♂ and 17 ♀) with a mean age of 70.9 (± 12.2) years were included in the study. In all 73 fractures of thoracic and lumbar vertebral bodies from the fourth thoracic vertebra to the fifth lumbar vertebra (Figure 1) were treated (1 to 6 fractures per patient). These included 20 patients with 39 osteoporotic vertebral body fractures and 15 patients with 34 fractures of neoplastic origin. Those with an underlying neoplastic disease included 12 patients with a multiple myeloma, one patient with metastatic breast cancer, one patient with metastatic colorectal cancer, and one patient with metastatic thymoma (Figure 2). The mean age of the fractures was 42.9 days (range, 1–180 days). The pre-interventional fracture grading according to Genant et al was on average 1.7 (± 1.0).

VAS scores were 8.6 (± 1.5) prior to the intervention, 3.8 (± 1.2) after the intervention, and 2.4 (± 1.4) after 6 months. ODI scores (%) at the corresponding time points were 81 (± 12), 42 (± 12) and 30 (± 14), respectively. Compared to pre-interventional values, the Wilcoxon rank sum test revealed that VAS as well as ODI scores were significantly reduced ($p < 0.001$) at the other time points.

Interventional complications such as symptomatic spinal or foraminal cement embolism, hemorrhage, or pulmonary cement embolism did not occur.

The procedure was performed in 56 of 73 treated segments (77 %) in unipedicular technique and in the remaining 23 % in bipedicular technique. The mean applied quantity of cement was 4.2 ml (± 1.9). During the six-month observation period, two fractures occurred in two of 20 patients with osteoporotic vertebral body fractures (10.0 %); these could be treated with no complications. Three patients were inaccessible for the six-month control investigation.

Discussion

According to our preliminary results and experience, radiofrequency kyphoplasty is a successful clinical procedure. Clinical outcomes such as pain relief on VAS and the level of limitation on the ODI were markedly improved. The technical application was associated with no symptomatic complications, particularly no radicular symptoms or spinal complications due to uncontrolled cement leakage or hemorrhage, and no pulmonary cement embolism.

The VAS score revealed a typical pattern: the substantial pain registered preoperatively improved rapidly postoperatively and the improvement was consolidated after six months. The same was true for the ODI: the very marked preoperative li-

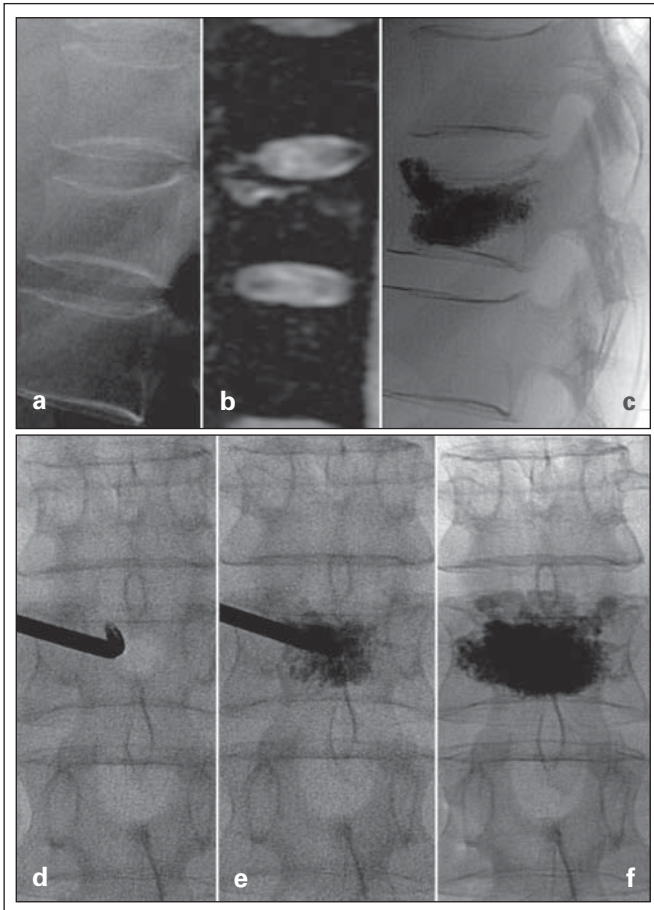


Figure 3: Case 1: Vertebral body compression fracture at the twelfth thoracic vertebra, age of fracture 7 days, Grade 1, **(a)** lateral X-ray, **(b)** sagittal PDw fs MRT, **(c)** lateral X-ray after treatment, **(d–f)** unilateral augmentation (antero-posterior fluoroscopy): after an initial central cement depot, additional PMMA was applied and finally the anterior margin of the vertebra was well supported. Controlled penetration to the posterior margin. Result: symmetrical distribution of cement, mild anterior reconstruction of height and correction of kyphosis.

mitation was improved on average to moderate limitation after six months. The patient population consisted of osteoporotic as well as of neoplastic vertebral body fractures. Similar efficacy has been reported for both groups in the published literature [3].

Analogous to the selection criteria used for other procedures, the selection of patients for radiofrequency kyphoplasty should follow the guidelines and should be based on interdisciplinary consensus. We believe that the indication for radiofrequency kyphoplasty does not essentially differ from that for other PMMA-based procedures. However, when treating younger non-oncological patients, it would be advisable to use a calcium phosphate cement. Due to its controlled applicability, radiofrequency kyphoplasty can be performed in cases of relative contraindications as well. These include, per guidelines, vertebra plana and lytic or traumatic involvement of the posterior margin.

The mean age of the fractures was about 6 weeks. In this setting the updated guidelines permit the use of early and effective pain therapy if required in the individual case [12]. Inconsistent results of current studies which doubt the efficacy of vertebroplasty and question its use [15, 16] are not yet convincing, have not been confirmed by other study groups, and contradict

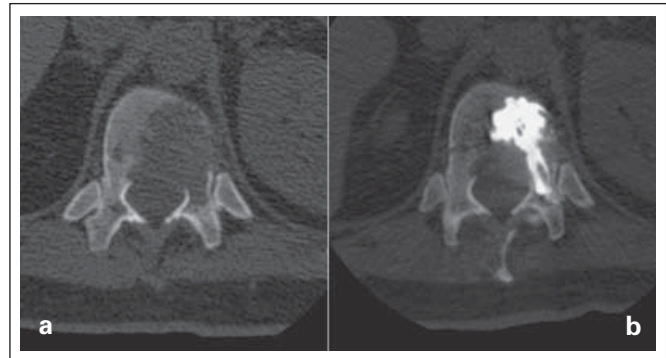


Figure 4: Case 2: Neoplastic osteolysis – thymoma metastasis. **(a)** Pre-interventional CT with extensive involvement of the posterior margin. **(b)** The control CT confirms safe and central introduction of the cement.

clinical experience as well as current and long-standing data [3, 17]. However, the results of the procedure do underline the need for careful selection of patients and exhaustion of conservative drug therapy regimens.

In the 6-month observation period, subsequent fractures occurred in two segments and in two patients (10 %). This value is in concordance with the range reported in the published literature [17, 18].

The material used for the procedure, such as the StabiliT[®] Vertebral Augmentation System and especially the ultra-high viscosity StabiliT[®] ER² Bone Cement and the VertecoR[™] MidLine Osteotome permit a safe and controlled intervention even in cases of primary application and under technically demanding conditions of treatment.

The concept of targeted fracture-specific pre-treatment using the navigational VertecoR[™]-MidLine osteotome is gentler than the creation of a large balloon cavity.

A more complex cement configuration compared to the balloon depot, interlocking in cancellous bone and a slightly lesser cement volume are possibly conducive to long-term stability in terms of achieving a more favorable – i.e. less stress-shielding – effect. The cement filling protects the surrounding trabeculae from mechanical loads in the sense that adequate stimulation is avoided during the remodeling process and demineralization starts to occur. It would appear that the ultra-high viscosity cement permits interlocking in most cases of osteoporotic and neoplastic vertebral body fractures. In the presence of highly osteoporotic bone it may be advisable to use less viscous cement. Independent of viscosity or thickness, the elasticity module or the stiffness of the cured cement (about 2 GPa) is maintained. This is comparable to the available PMMA cements and influences stress shielding in addition to the configuration of the cement itself.

The term “ultra-high viscosity” only refers to the yet unsettled cement at the time of its application in the vertebral body.

The ultra-high viscosity StabiliT[®] ER² Bone Cement in conjunction with the remote-operated hydraulic assembly system

permits the clinician to perform a very well controlled intervention. No symptomatic complications were encountered. Even in the presence of apparent destruction of the posterior margin of the vertebral body (Figure 4) the cement could be applied without complications. Regarding the application procedure, beginning or actual cement leakage can be controlled. By repeated interruption of the application through the entire working time of approximately 30 minutes, the introduced cement can harden and leakages can thus be sealed. The cement injection is then continued until the desired result is achieved. Cement embolisms are also avoided by this procedure.

■ Relevance in clinical practice

- Radiofrequency kyphoplasty is an evolutionary procedure of kyphoplasty that permits a safe intervention because of the availability as well as the prolonged and mechanically controlled application of an ultra-high viscosity PMMA cement.
- Avoiding creation of a large cavity and the unilateral access commonly employed when using the VertebroR™ MidLine Osteotome ensure gentle handling of the substance.
- Compared to its predecessors, radiofrequency kyphoplasty is a procedure of equivalent clinical efficacy, yet potentially less traumatic and safer.

References:

1. Galibert P, Deramond H, Rosat P, et al. [Preliminary note on the treatment of vertebral angioma by percutaneous acrylic vertebroplasty]. *Neurochirurgie* 1987; 33: 166–8.
2. Lieberman IH, Dudeney S, Reinhardt MK, et al. Initial outcome and efficacy of „kyphoplasty“ in the treatment of painful osteoporotic vertebral compression fractures. *Spine (Phila Pa 1976)* 2001; 26: 1631–8.
3. McGirt MJ, Parker SL, Wolinsky JP, et al. Vertebroplasty and kyphoplasty for the treatment of vertebral compression fractures: an evidenced-based review of the literature. *Spine J* 2009; 9: 501–8.
4. Layton KF, Thielen KR, Koch CA, Luetmer PH, et al. Vertebroplasty, first 1000 levels of a single center: evaluation of the outcomes and complications. *AJNR Am J Neuroradiol* 2007; 28: 683–9.
5. Kim YJ, Lee LW, Park KW, et al. Pulmonary cement embolism after percutaneous vertebroplasty in osteoporotic vertebral compression fractures: incidence, characteristics, and risk factors. *Radiology* 2009; 251: 250–9.
6. Lee BJ, Lee SR, Yoo TY, Paraplegia as a complication of percutaneous vertebroplasty with polymethylmethacrylate: a case report. *Spine (Phila Pa 1976)* 2002; 27: E419–22.
7. Kim SY, Seo JB, Do KH, et al. Cardiac perforation caused by acrylic cement: a rare complication of percutaneous vertebroplasty. *AJR Am J Roentgenol* 2005; 85: 1245–7.
8. Lim KJ, Yoon SZ, Jeon YS, et al. An intra-atrial thrombus and pulmonary thromboembolism as a late complication of percutaneous vertebroplasty. *Anesth Analg* 2007; 104: 924–6.
9. Scoop R, Eskridge J, Britz GW. Paradoxical cerebral arterial embolization of cement during intraoperative vertebroplasty: case report. *AJNR Am J Neuroradiol* 2002; 23: 868–70.
10. Hierholzer J, Fuchs H, Westphalen K, et al. [Percutaneous vertebroplasty – the role of osseous phlebography]. *Rofo* 2005; 177: 386–92.
11. Helmberger T, Bohnhoff K, Hierholzer J, et al. [Guidelines of the German Radiological Society for percutaneous vertebroplasty]. *Radiologe* 2003; 43: 703–8.
12. Dachverband Osteologie e.V. DVO-Leitlinie 2009 zur Prophylaxe, Diagnostik und Therapie der Osteoporose bei Erwachsenen – Langfassung. *Osteologie* 2009; 18: 304–28.
13. Mannion AF, Junge A, Fairbank JC, et al. Development of a German version of the Oswestry Disability Index. Part 1: cross-cultural adaptation, reliability, and validity. *Eur Spine J* 2006; 15: 55–65.
14. Genant HK, Wu CY, van Kuijk C, Nevitt MC. Vertebral fractures assessment using a semiquantitative technique. *J Bone Miner Res* 1993; 8: 1137–8.
15. Buchbinder R, Osborne RH, Ebeling PR, et al. A randomized trial of vertebroplasty for painful osteoporotic vertebral fractures. *N Engl J Med* 2009; 361: 557–68.
16. Kallmes DF, Comstock BA, Heagerty PJ, et al. A randomized trial of vertebroplasty for osteoporotic spinal fractures. *N Engl J Med* 2009; 361: 569–79.
17. Wardlaw D, Cummings SR, Van Meirhaeghe J, et al. Efficacy and safety of balloon kyphoplasty compared with non-surgical care for vertebral compression fracture (FREE): a randomised controlled trial. *Lancet* 2009; 373: 1016–24.
18. Hierholzer J, Fuchs H, Westphalen K, et al. Incidence of symptomatic vertebral fractures in patients after percutaneous vertebroplasty. *Cardiovasc Intervent Radiol* 2008; 31: 1178–83.

Mitteilungen aus der Redaktion

Besuchen Sie unsere zeitschriftenübergreifende Datenbank

☒ [Bilddatenbank](#)

☒ [Artikeldatenbank](#)

☒ [Fallberichte](#)

e-Journal-Abo

Beziehen Sie die elektronischen Ausgaben dieser Zeitschrift hier.

Die Lieferung umfasst 4–5 Ausgaben pro Jahr zzgl. allfälliger Sonderhefte.

Unsere e-Journale stehen als PDF-Datei zur Verfügung und sind auf den meisten der marktüblichen e-Book-Readern, Tablets sowie auf iPad funktionsfähig.

☒ [Bestellung e-Journal-Abo](#)

Haftungsausschluss

Die in unseren Webseiten publizierten Informationen richten sich **ausschließlich an geprüfte und autorisierte medizinische Berufsgruppen** und entbinden nicht von der ärztlichen Sorgfaltspflicht sowie von einer ausführlichen Patientenaufklärung über therapeutische Optionen und deren Wirkungen bzw. Nebenwirkungen. Die entsprechenden Angaben werden von den Autoren mit der größten Sorgfalt recherchiert und zusammengestellt. Die angegebenen Dosierungen sind im Einzelfall anhand der Fachinformationen zu überprüfen. Weder die Autoren, noch die tragenden Gesellschaften noch der Verlag übernehmen irgendwelche Haftungsansprüche.

Bitte beachten Sie auch diese Seiten:

[Impressum](#)

[Disclaimers & Copyright](#)

[Datenschutzerklärung](#)