

Journal für
Mineralstoffwechsel
Zeitschrift für Knochen- und Gelenkserkrankungen
Orthopädie • Osteologie • Rheumatologie

**Preliminary experimental results
of radiofrequency-cement-augmented
and cannulated pedicle screws**

Goost H, Deborre C, Kabir K

Weber O, Wirtz DC, Karius T

Pflugmacher R

Journal für Mineralstoffwechsel &

Muskuloskelettale Erkrankungen

2011; 18 (Supplementum 1), 23-25

Homepage:

**[www.kup.at/
mineralstoffwechsel](http://www.kup.at/mineralstoffwechsel)**

**Online-Datenbank mit
Autoren- und Stichwortsuche**

Member of the



Indexed in SCOPUS/EMBASE/Excerpta Medica
www.kup.at/mineralstoffwechsel



Offizielles Organ der
Österreichischen Gesellschaft
zur Erforschung des Knochens
und Mineralstoffwechsels



Österreichische Gesellschaft
für Orthopädie und
Orthopädische Chirurgie



Österreichische
Gesellschaft
für Rheumatologie

Krause & Pachernegg GmbH · VERLAG für MEDIZIN und WIRTSCHAFT · A-3003 Gablitz

P.b.b. GZ02Z031108M, Verlagspostamt: 3002 Purkersdorf, Erscheinungsort: 3003 Gablitz

Erschaffen Sie sich Ihre ertragreiche grüne Oase in Ihrem Zuhause oder in Ihrer Praxis

Mehr als nur eine Dekoration:

- Sie wollen das Besondere?
- Sie möchten Ihre eigenen Salate, Kräuter und auch Ihr Gemüse ernten?
- Frisch, reif, ungespritzt und voller Geschmack?
- Ohne Vorkenntnisse und ganz ohne grünen Daumen?

Dann sind Sie hier richtig



Preliminary experimental results of radiofrequency-cement-augmented and cannulated pedicle screws

H. Goost, C. Deborre, K. Kabir, O. Weber, D. C. Wirtz, T. Karius, R. Pflugmacher

Abstract: The risk of cut-out of a pedicle screw is high in the presence of osteoporotic bone. In cadaver studies it was found that cement augmentation of pedicle screws markedly increases pull-out forces. However, the use of conventional low viscosity vertebroplasty or kyphoplasty cement is associated with the risk of cement extravasation. The risk might be reduced by using high viscosity, radiofrequency-activated bone cement.

After performing DEXA scans, six fresh-frozen vertebral bodies of different bone densities were obtained from cadavers. Two pedicle screws

(WSI Expertise-Inject, Peter Brehm, Germany) were placed in the pedicles. About 3 ml of radiofrequency-activated, ultra-high viscosity cement (ER2 Bone Cement, DFine Europe GmbH, Germany) was injected through the right pedicle. The left pedicle screw was left uncemented and served as control. Axial pullout tests were performed using a material testing device (Zwick/Roell Zmartpro, Ulm, Germany). The tests revealed that cement-augmented pedicle screws were able to withstand markedly higher pullout forces. Extravasation of cement did not occur.

The value of the study is limited by the fact that only six samples were investigated. Further cadaver studies and clinical evaluation will be needed in the future. However, this pilot study showed that combining cannulated pedicle screws with ultra-high viscosity bone cement is a successful approach. Revision due to cut-out and complications secondary to cement extravasation can be reduced by this method. **J Miner Stoffwechs 2011; 18 (Supplement 1): 23–5.**

■ Introduction

In a society with an increasing life expectancy and an advancing mean age of the population, the poor quality of bone in patients with osteoporosis is a common and technically demanding challenge for the spine surgeon, because the risk of failure of the bone-implant interface is markedly increased when pedicle screws are used in the osteoporotic vertebral body [1].

In several cadaver studies it was found that augmentation of a pedicle screw with cements like calcium phosphate or polymethylmethacrylate (PMMA) significantly increases pullout forces [2–4]. Clinically, the practicability of special cannulated pedicle screws has led to their widespread acceptance for the purpose cement augmentation [5]. Augmentation with conventional low-viscosity cements causes similar complication rates as those encountered with vertebroplasty or conventional kyphoplasty. These primarily consist of cement leakage into the spinal canal, the neuroforamina or paravertebral veins [6]. In a hitherto unpublished survey conducted by H. Goost, 55 % of the surveyed persons reported complications like extravasation in the ventral or dorsal aspect, incorrect positioning of the screw, or cement embolism.

The combination of a cannulated pedicle screw and radiofrequency-activated, ultra-high viscosity cement might minimize the previously mentioned risks of extravasation. Therefore, the aim of the present study was to test the pullout forces of a cannulated pedicle screw with augmentation by radiofrequen-

cy-activated PMMA in a cadaver model, and to observe the distribution of cement in this setting.

■ Methods

Using DEXA-Scan (Siemens QDR 2000), fresh-frozen cadaver spines were investigated with regard to the presence of osteoporosis ($BMD \leq 0.8 \text{ g/cm}^3$): Four osteoporotic and non-osteoporotic vertebral bodies of various persons were identified and freed of all soft tissue. The pedicle was visualized clinically and radiographically by the use of an image converter.

The pedicle was perforated with an awl. The Nitinol guidewire was then pushed forward into the vertebral body through the awl. The cannulated awl was removed and the pedicle screw (WSI Expertise Inject 6 x 45 mm, Peter Brehm Company, Weisendorf, Germany) rotated inward through the guidewire. The cementing adapter was positioned and 2.5 to 3 ml of ultra-high viscosity PMMA cement (StabiliT ER² Bone Cement, DFine GmbH, Germany) was applied mechanically (using the StabiliT[®] Vertebral Augmentation System, DFine GmbH, Germany) through the right pedicle screw. The left pedicle screw was left uncemented and served as control (Figure 1). Immediately before the cement leaves the StabiliT System it passes through a heating element, warmed by radiofrequency (RF), resulting in delivery of an ultra-high viscosity cement. Cement is delivered using an automated controller that contains a hydraulic drive and a RF generator (MultiPlex Controller, DFine GmbH, Germany), by operating a manual switch, at a distance of 3 meters from the source of radiation. Using a customized portion of cement, 4 to 6 pedicle screws can be augmented in a period of about 30 minutes. After radiographic documentation of the position of the screw, axial pullout was tested in a material testing machine (Zwick/Roell Zmartpro, Ulm, Germany).

From the Clinic and Policlinic of Orthopedics and Traumatology, University Clinic, Bonn, Germany

Correspondence address: Dr. med. Hans Goost, Klinik und Poliklinik für Orthopädie und Unfallchirurgie, Universitätsklinikum Bonn, Sigmund-Freud-Str. 25, D-53125 Bonn; E-Mail: hans.goost@ukb.uni-bonn.de

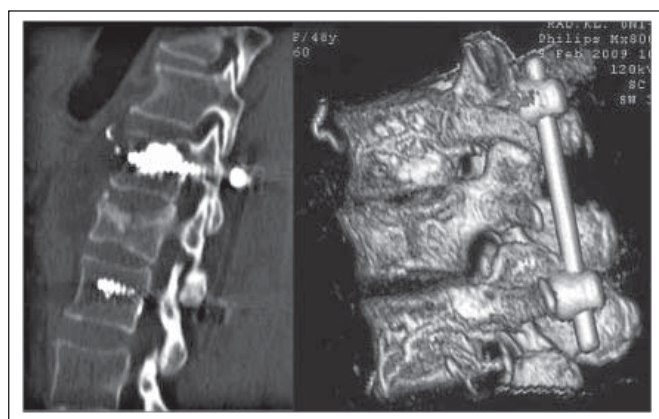


Figure 1: Inhomogeneous distribution of cement/extravasation

Results

The above mentioned procedure was performed in six selected vertebral bodies with no complications such as congestion of cement during application or cement extravasation. Post-interventional control CT's confirmed the regular position of the pedicle screws and homogeneous distribution of cement in the vertebral body. In all vertebral bodies the cement was deposited in the middle or posterior third.

Pullout forces in the osteoporotic vertebral body could be massively increased by cement augmentation. A massive increase in pullout forces was also noted in the non-osteoporotic vertebral body, but was less pronounced than that in the osteoporotic one (Table 1, Figure 2).

Discussion

In the present experimental investigation, the delivery of an ultra-high viscosity StabiliT ER² Bone Cement through a cannulated screw proved to be a safe means of achieving significant enhancement of the pullout forces of a pedicle screw in osteoporotic bone. Furthermore, no complications – in particular no cement leakages – were encountered.

Usually osteoporotic vertebral compression fractures can be treated by vertebroplasty or conventional kyphoplasty [7]. However, osteoporotic vertebral body fractures with involvement of the posterior margin (from the fracture type A3.1 onward according to the AO/Magerl classification) need additional surgical stabilization through internal fixation [8]. In addition to fracture stabilization, the treatment of degenerative spinal diseases requires the use of dorsal instrumentation in the presence of osteoporosis as well.

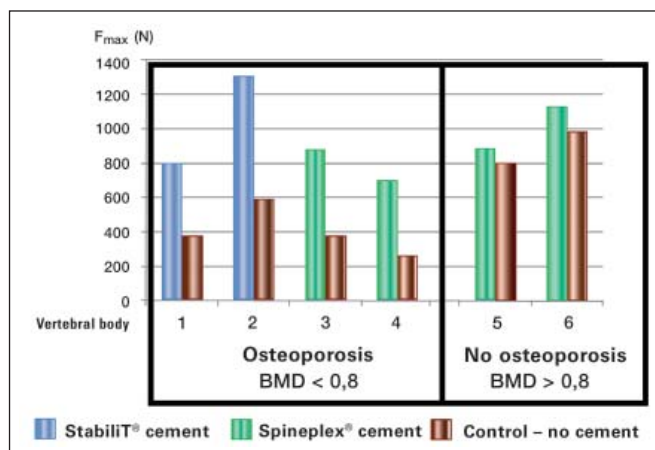


Figure 2: Pullout forces. BMD = bone mineral density; F_{max} = maximal pullout force

Guidelines as to when and how cement augmentation of pedicle screws should be performed do not exist. At the present time, the indication as well as the type of application are left to the surgeon's discretion (Table 2).

The following procedures are used:

- Insertion of the pedicle screw, backing out the screw, injection of kyphoplasty cement and reinsertion of the screw
- Insertion of the pedicle screw, backing out the screw, kyphoplasty with cement application, reinsertion of the screw
- Insertion of a special cannulated screw and injection of cement into the screw

The fact that pullout forces in the osteoporotic vertebral body are significantly enhanced by cement augmentation of a pedicle screw has been conclusively proven in several cadaver studies. However, the procedure that should be given preference has not been clearly established yet. When conventional low-viscosity cement is used for augmentation, it may leak out of the vertebral body and cause complications. Spinal and paravertebral cement leakages as well as fatal incidents such as pulmonary embolism have been reported in the published literature [9–11]. Besides, the clinical application of low-viscosity cement is not entirely devoid of complications. In our clinical study using Spineplex[®] we found that this cement offers very short working times. If the cement is too fluid at the time of application, it flows out of the vertebral body and causes visible leakage into paravertebral veins (Figure 1). Thus, this approach also does not permit the surgeon to deliver an adequate amount of cement in the vertebral body. In cases of delayed application the Spineplex[®] cement hardens too rapidly so that cementing of more than two screws becomes a hectic task for the surgeon.

Table 1: Summary of preparations

Height of vertebral body	Age	Gender	BMD	Cement	F _{max} not augmented	F _{max} augmented
L3	81	m	0.702	StabiliT [®]	376	803
L2	85	w	0.71	StabiliT [®]	591	1310
L2	84	w	0.747	Spineplex [®]	381	882
L4	91	w	0.73	Spineplex [®]	265	702
L5	85	w	0.905	Spineplex [®]	799	886
L1	92	w	1.342	Spineplex [®]	982	1130

BMD = bone mineral density; F_{max} = maximal pullout force

Table 2: Indications for cement augmentation of pedicle screws

- Osteoporosis
- Revision after pedicle screw cut-out
- Avoidance of instrumentation over long distances

This can be avoided by the use of ultra-high viscosity cement like StabiliT ER² Bone Cement (DFine GmbH, Germany) which has a working time of about 30 minutes and was used in the present experimental study.

A limitation of this study is the small number of samples. Further evaluation in cadavers and the clinical setting will therefore be necessary. However, by way of a pilot study the present investigation showed that combining the two procedures is a successful technical approach. Therefore, this procedure may well be introduced rapidly in the clinical practice. It would offer patients with osteoporosis the advantage of a markedly reduced rate of revision surgery due to pedicle screw cut-outs as well as a reduced rate of complications due to cement leakage.

■ Clinical relevance

In clinical routine, the application of radiofrequency-warmed bone cement through a cannulated pedicle screw would signify a major improvement because the rate of cement extravasations can be markedly reduced and pullout forces increased. Furthermore, the procedure is associated with less radiation exposure for the surgeon because cement augmentation can be performed mechanically at a safe distance from the source of radiation. Finally, the patient also benefits from the reduced risk of cement extravasation and the possibility of minimally invasive insertion of screws and cement augmentation.

References:

1. Halvorson TL, Kelley LA, Thomas KA, Whitecloud TS 3rd, Cook SD. Effects of bone mineral density on pedicle screw fixation. *Spine (Phila Pa 1976)* 1994; 19: 2415–20.
2. Moore DC, Maitra RS, Farjo LA, et al. Restoration of pedicle screw fixation with an in situ setting calcium phosphate cement. *Spine (Phila Pa 1976)* 1997; 22: 1696–705.
3. Sarzier JS, Evans AJ, Cahill DW. Increased pedicle screw pullout strength with vertebroplasty augmentation in osteoporotic spines. *J Neurosurg* 2002; 96: 309–12.
4. Frankel BM, D'Agostino S, Wang C. A biomechanical cadaveric analysis of polymethylmethacrylate-augmented pedicle screw fixation. *J Neurosurg Spine* 2007; 7: 47–53.
5. Chen LH, Tai CL, Lai PL, et al. Pullout strength for cannulated pedicle screws with bone cement augmentation in severely osteoporotic bone: influences of radial hole and pilot hole tapping. *Clin Biomech (Bristol, Avon)* 2009; 24: 613–8.
6. Felder-Puig R, Piso B, Guba B, et al. Kyphoplastie und Vertebroplastie bei osteoporotischen Wirbelkörperkompressionsfrakturen: Systematischer Review. *Orthopaede* 2009; 38: 606–15.
7. Pflugmacher R, Kandziora F, Schroder R, et al. Vertebroplasty and kyphoplasty in osteoporotic fractures of vertebral bodies – a prospective 1-year follow-up analysis. *Röfo* 2005; 177: 1670–6.
8. Pflugmacher R, Agarwal A, Kandziora F, et al. Balloon kyphoplasty combined with posterior instrumentation for the treatment of burst fractures of the spine – 1-year results. *J Orthop Trauma* 2009; 23: 126–31.
9. Temple JD, Ludwig SC, Ross WK, et al. Catastrophic fat embolism following augmentation of pedicle screws with bone cement: a case report. *J Bone Joint Surg Am* 2002; 84-A: 639–42.
10. Jung MY, Shin DA, Hahn IB, Kim TG, Huh R, Chung SS. Serious complication of cement augmentation for damaged pilot hole. *Yonsei Med J* 2010; 51: 466–8.
11. Pillich DT BJ, Müller JU, Schroeder HWS. Cement augmenting pedicle screws – reliability in patients with osteoporosis and tumor-related osteolysis. 59. Jahrestagung der Deutschen Gesellschaft für Neurochirurgie, 2008, Würzburg.

Mitteilungen aus der Redaktion

Besuchen Sie unsere zeitschriftenübergreifende Datenbank

☒ [Bilddatenbank](#)

☒ [Artikeldatenbank](#)

☒ [Fallberichte](#)

e-Journal-Abo

Beziehen Sie die elektronischen Ausgaben dieser Zeitschrift hier.

Die Lieferung umfasst 4–5 Ausgaben pro Jahr zzgl. allfälliger Sonderhefte.

Unsere e-Journale stehen als PDF-Datei zur Verfügung und sind auf den meisten der marktüblichen e-Book-Readern, Tablets sowie auf iPad funktionsfähig.

☒ [Bestellung e-Journal-Abo](#)

Haftungsausschluss

Die in unseren Webseiten publizierten Informationen richten sich **ausschließlich an geprüfte und autorisierte medizinische Berufsgruppen** und entbinden nicht von der ärztlichen Sorgfaltspflicht sowie von einer ausführlichen Patientenaufklärung über therapeutische Optionen und deren Wirkungen bzw. Nebenwirkungen. Die entsprechenden Angaben werden von den Autoren mit der größten Sorgfalt recherchiert und zusammengestellt. Die angegebenen Dosierungen sind im Einzelfall anhand der Fachinformationen zu überprüfen. Weder die Autoren, noch die tragenden Gesellschaften noch der Verlag übernehmen irgendwelche Haftungsansprüche.

Bitte beachten Sie auch diese Seiten:

[Impressum](#)

[Disclaimers & Copyright](#)

[Datenschutzerklärung](#)