Journal of Clinical and Basic Cardiology

An Independent International Scientific Journal

Journal of Clinical and Basic Cardiology 2000; 3 (2), 81-86

Atherosclerotic plaque rupture: an overview

Pasterkamp C, Falk E

Homepage:

www.kup.at/jcbc

Online Data Base Search for Authors and Keywords

Indexed in
Chemical Abstracts
EMBASE/Excerpta Medica

Krause & Pachernegg GmbH · VERLAG für MEDIZIN und WIRTSCHAFT · A-3003 Gablitz/Austria

Atherosclerotic Plaque Rupture: an Overview

G. Pasterkamp, E. Falk[1]

Atherosclerotic luminal narrowing is determined by plaque mass and local change in vessel size (remodeling). Regardless of its size, a plaque may rupture with high risk of subsequent thrombus-mediated acute clinical events such as myocardial infarction and stroke. The risk of plaque rupture depends more on plaque type than on plaque size or stenosis severity. Major determinants of a plaque's vulnerability to rupture are: 1) size and consistency of the lipid-rich atheromatous core; 2) thickness of the fibrous cap covering the core; and 3) ongoing inflammation and repair within the cap. Plaque disruption tends to occur at points where the plaque surface is weakest and most vulnerable which coincide with points where stresses, resulting from biomechanical and haemodynamic forces acting on plaques, are concentrated. Therefore, both plaque vulnerability (intrinsic disease) and rupture triggers (extrinsic forces) are important for plaque disruption. The former predisposes the plaque to rupture while the latter may precipitate it. The resultant thrombotic response determines the clinical presentation and the outcome. *J Clin Basic Cardiol 2000; 3: 81–6.*

Key words: atherosclerosis, plaque rupture, remodeling, coronary artery disease

Coronary atherosclerosis starts early in life but it takes decades to develop mature plaques responsible for ischaemic heart disease (IHD). Proliferation of SMC, matrix synthesis and lipid accumulation may narrow the arterial lumen gradually and ultimately lead to myocardial ischaemia and anginal pain but survival is good if thrombotic complications can be prevented. It is thrombosis, superimposed on mature plaques, that may turn an otherwise benign disease into a life-threatening condition, being mainly responsible for the acute coronary syndromes of unstable angina, acute myocardial infarction and sudden coronary death [1, 2]. Therefore, for event-free survival, the vital question is not why atherosclerosis develops but rather why some plaques remain thrombus-resistent and innocuous while other plaques, after years of indolent growth, become thrombus-prone and life-threatening. As to that, plaque composition (vulnerability) and plaque thrombogenicity have emerged as being much more important than plaque size and stenosis severity; plaques containing a core of soft lipid-rich atheromatous "gruel" are particularly dangerous because such plaques are unstable and vulnerable to rupture whereby highly thrombogenic plaque components are exposed to the flowing blood [3–6]. Plaque disruption, or fissuring, with thrombosis superimposed is the most frequent cause of the acute coronary syndromes [1–3].

Atherogenesis, remodeling, and luminal narrowing

In general, plaque is still considered the only determinant of luminal narrowing in atherosclerosis despite the fact that compensatory arterial enlargement tending to preserve the lumen is often seen with plaque growth [7, 8]. More recently, the opposite phenomenon (arterial shrinkage during plaque growth) has also been described [9]. That is, arteries are not only capable of remodeling in order to compensate for plaque growth by enlargement but shrinkage with accelerated luminal narrowing may also occur [8–12]. Thus, both plaque formation and arterial remodeling play a role in luminal narrowing caused by atherosclerosis.

Plaque formation

In patients with IHD, the coronary arteries are diffusely involved with confluent "plaquing". The composition, consistency, vulnerability and thrombogenicity of individual plaques vary greatly without any obvious relation to the well-known risk factors for clinical disease. Most importantly, there is no simple relation among plaque type, plaque size, and stenosis severity [13].

As the name "athero-sclerosis" implies, mature plaques consist typically of two main components: atheromatous "gruel" that is lipid-rich and soft and *sclerotic* tissue that is collagen-rich and hard. Although the sclerotic component usually is by far the most voluminous, constituting > 70 % of an average stenotic coronary plaque [14, 15], it is a relatively benign component because collagen secreted by SMC probably stabilizes plaques, protecting them against disruption [16]. In contrast, the atheromatous component is by far the most dangerous, because the soft atheromatous gruel together with local inflammatory processes destabilizes plaques, making them vulnerable to rupture with high risk of subsequent thrombus formation.

The atheromatous core within a plaque lacks supporting collagen; it is rich in extracellular lipids, predominantly cholesterol and its esters [17]; it is avascular and hypocellular (macrophage foam cells are, however, frequently present at the periphery of the core) [18]; and it is usually soft like gruel. It is generally believed that macrophage foam cell death by necrosis or apoptosis [19, 20], possibly due to cytotoxic effects of oxidized LDL taken up by macrophages via scavenger receptors, plays an important role in extracellular lipid accumulation and core formation [21]. Insudating lipoproteins trapped and retained within the extracellular space, without first being taken up and subsequently released by macrophages, may, however, also contribute to extracellular lipid accumulation, core formation and core enlargement [22, 23].

At autopsy, Mann and Davies studied 160 mature coronary plaques and found no relation between plaque size or stenosis severity and the vulnerability of the lesion [13] which may explain why stenosis severity evaluated by angi-

From the Experimental Cardiology Laboratory, Utrecht Universital Hospital, Utrecht, The Netherlands, and the [1]Department of Cardiology, Aarhus University Hospital (Skejby), Aarhus, Denmark
Correspondence to: Prof. Erling Falk, Department of Cardiology, Research, Aarhus University Hospital (Skejby), DK-8200 Aarhus N, Denmark; E-mail:skejef@aau.dk

ography is a poor predictor for subsequent progression to occlusion and/or myocardial infarction (supposed to originate from vulnerable plaques) [3, 24, 25]. Recent studies suggest, however, that besides being much more numerous than stenotic angina-producing plaques [3], mild-to-moderately stenotic plaques are probably more prone to rupture because vulnerable plaques appear to possess a particular potential for arterial enlargement during plaque growth tending to preserve the lumen [26, 27]. Thus, coronary angiography is not a good method to screen for vulnerable plaques, partly because of their small size and partly because of vascular remodeling.

Arterial remodeling

In experimental primate atherosclerosis, the artery adapts to lesion formation by enlargement resulting in a long prestenotic phase of atherosclerosis [7]. Glagov et al. studied atherosclerotic enlargement in histological cross-sections of left-main coronary arteries obtained from 136 human hearts [8]. They found that coronary arteries enlarge proportionally to the increase in plaque area and that the formation of a functionally important lumen stenosis is delayed until the lesion occupies approximately 40 percent of the area within the internal elastic lamina. Even overcompensatory enlargement of the coronary artery with increase of the luminal cross-sectional area was observed [8]. Their findings on (over-)compensatory enlargement were supported by several *in vivo* studies in which geometric remodeling was studied by epicardial [28] and intravascular ultrasound [27, 29–32].

However, in atherosclerosis the extent and type of remodeling may vary: not only compensatory enlargement but also failure of enlargement or even shrinkage may be observed [9–12]. By assessing local changes in vessel area in response to focal plaque growth in the femoral artery, we frequently observed that the decrease in lumen area could not be attributed to an increase in plaque size alone [9]. Regardless of arterial type, shrinkage of atherosclerotic arteries is responsible for part of the decrease in lumen area. In addition, less luminal narrowing is observed in compensatory enlarged arterial segments compared to shrunken segments. Thus, compensatory enlargement prevents and shrinkage accelerates luminal narrowing during atherogenesis [9]. Until now, compensatory enlargement has been demonstrated in atherosclerotic coronary arteries [8, 29–32], femoral arteries [9–11], iliac arteries [32] and carotid arteries [33]. Shrinkage has been demonstrated in femoral [9–11], coronary [11, 12], iliac, carotid and renal arteries [11]. The type of arterial remodeling (shrinkage or enlargement) differs among arteries [11].

Arterial enlargement during plaque growth tends to preserve the lumen and should thus be considered beneficial if not for the "paradoxical" observation that compensatory enlargement is more frequently associated with vulnerable than with stable plaques [26, 27]. Thus, arterial enlargement during plaque growth prevents luminal narrowing but, nevertheless, such non-stenotic lesions are "paradoxically" more dangerous than stenotic lesions because they are more vulnerable and prone to rupture, increasing the risk of a thrombus-mediated acute heart attack [26].

Plaque vulnerability

There are three major determinants of a plaque's vulnerability to rupture: 1) the size and consistency of the atheromatous core; 2) the thickness of the fibrous cap covering the core; and 3) inflammation and repair within the cap.

Core size and consistency

The size of the atheromatous core is critical for the stability of individual plaques. Gertz and Roberts reported the composition of plaques in 5-mm segments from 17 infarct-related arteries examined *post mortem* and found much larger atheromatous cores in the 39 segments with plaque rupture than in the 229 segments with intact surface (32 % and 5–12 % of plaque area, respectively) [34]. By studying aortic plaques, Davies et al. found a similar relation between core size and plaque rupture and they identified a critical threshold; intact aortic plaques containing a core occupying more than 40 % of the plaque area were considered particularly vulnerable and at high risk of rupture and thrombosis [35].

The consistency of the core, which probably also is important for the stability of a plaque, depends on temperature and lipid composition. The core gruel usually has a consistency like toothpaste at room temperature *post mortem* and it is even softer at body temperature *in vivo* [17]. If temperatures increase, like with inflammation [36], the core becomes softer. Liquid cholesteryl esters soften the gruel while crystalline cholesterol has the opposite effect [17]. Based on animal experiments [17, 37], lipid-lowering therapy in man is expected to deplete plaque lipid with an overall reduction in the liquid and mobile cholesteryl esters and a relative increase in the solid and inert crystalline cholesterol, theoretically resulting in a stiffer and more stable plaque [38].

Cap thickness

Thickness, cellularity, matrix, strength and stiffness of fibrous caps vary widely. Cap thinning and reduced collagen content increase a plaque's vulnerability to rupture [39]. Caps of eccentric plaques are often thinnest and most heavily foam cell infiltrated at their shoulder regions where they most frequently rupture [40]. Collagen is important for the tensile strength of tissues, and ruptured aortic caps contain less collagen than intact caps. For fibrous caps of the same tensile strength, caps covering mildly or moderately stenotic plaques are probably more prone to rupture than caps covering stenotic plaques because the former have to bear a greater circumferential tension (according to Laplace's law) [39].

Cap inflammation and repair

Disrupted fibrous caps usually are heavily infiltrated by macrophage foam cells [41], and recent observations revealed that such rupture-related macrophages are activated, indicating ongoing inflammation at the site of plaque disruption [42]. For eccentric plaques, the shoulder regions are sites of predilection for both active inflammation (endothelial activation and macrophage infiltration) and disruption [40, 43], and mechanical testing of aortic fibrous caps indicate that foam cell infiltration indeed weakens caps locally, reducing their tensile strength [44]. Van der Wal et al. identified superficial macrophage infiltration in plaques beneath all 20 coronary thrombi examined, whether or not the underlying plaque was disrupted or just eroded [42]. These *post mortem*-studies of patients dying from coronary thrombosis have been confirmed by an *in vivo* study of atherectomy specimens obtained from culprit lesions responsible for stable angina, unstable rest angina or non-Q-wave infarction [45]. Culprit lesions responsible for the acute coronary syndromes contained significantly more macrophages than did lesions responsible for stable angina pectoris (14 % versus 3 % of plaque tissue occupied by macrophages) [45].

Macrophages, but also other types of cells in plaques, may secrete proteolytic enzymes, among others matrix

metalloproteinases (MMPs) that may degrade the plaque matrix and thus predispose plaques to rupture [46–48]. MMP is a collective term for matrix proteases that encompass different MMP subtypes. Most investigated MMPs with respect to atherogenesis and plaque vulnerability are collagenase MMP-1, gelatinases MMP-2 and MMP-9, and stromelysin MMP-3. Recently, MMP-1 was found to be expressed particularly in the shoulders of eccentric plaques which are regions of high circumferential stress [49]. MMP-2 and MMP-9 have been identified by functional assays (zymography) in plaques with vulnerable features by histology [48]. By the way, MMP-activity is also enhanced in aortic aneurysms [50, 51]. Thus, MMPs are assumed to play an important role in plaque destabilization and provide a potential target in the prevention of plaque rupture [52, 53].

Activated mast cells in plaques may secrete powerful proteolytic enzymes, and mast cells are indeed present in shoulder regions of mature plaques and at sites of disruption but usually at low density [54, 55]. T-lymphocytes are also present in plaques and they could promote MMP expression in adjacent cells via CD-40 ligation [56] or they could inhibit collagen synthesis by smooth muscle cells via interferon-gamma secretion [57].

Regarding infection, several infectious agents have gained increasing interest over the past few years, including *Herpes simplex virus, Cytomegalo virus, Chlamydia pneumoniae, and Helicobacter pylori.* Seroepidemiological data indicate a higher prevalence of past or present infection among patients with acute coronary syndromes [58, 59]. However, the association is somewhat invalidated by a high prevalence of these infections in the general population. Chlamydia pneumoniae has been identified in atherosclerotic plaques [60] but it is still unknown whether this microorganism is present just as an innocent bystander or it plays a pathogenetic role in plaque development, vulnerability, disruption, and/or thrombogenecity [61–63].

The role of macrophages in plaque destabilization is even more evident considering that activated monocytes/macrophages may express tissue factor and thus could play a detrimental role also after plaque disruption by promoting thrombin generation and luminal thrombosis [5, 6, 64, 65]. Active tissue factor is indeed present in culprit lesions responsible for the life-threatening acute coronary syndromes [65].

In contrast to macrophages, local loss of SMCs could result in impaired healing and repair and thus lead to gradual plaque destabilization, culminating in plaque disruption and thrombosis [35, 57].

Plaque rupture

Rupture of vulnerable plaques occurs frequently. It is followed by variable amount of luminal thrombosis and/or haemorrhage into the soft gruel, causing rapid growth of the lesion. Autopsy data indicate that 9 % of "normal" healthy persons are walking around with disrupted plaques (without superimposed thrombosis) in their coronary arteries, increasing to 22 % in persons with diabetes or hypertension [66], and one or more disrupted plaques, with or without superimposed thrombosis, are usually present in coronary arteries of patients dying of IHD [41, 67]. Disruption of the plaque surface occurs most often where the cap is thinnest and most heavily infiltrated by macrophages and therefore weakest, namely at the cap's shoulders [3, 40]. The weak shoulder regions are, however, also points where biomechanical and haemodynamic forces acting on plaques often are concentrated [40, 68]. Therefore, the risk of plaque disruption is related to both *intrinsic* plaque features (actual vulnerability) and *extrinsic* stresses imposed on plaque (rupture triggers); the former predispose a plaque to rupture while the latter may precipitate it, if the plaque is vulnerable. As the presence of a vulnerable plaque is a prerequisite for plaque disruption, vulnerability is probably more important than triggers in determining the risk of a future heart attack. If no vulnerable plaques are present in the coronary arteries, there is no rupture-prone substrate for a potential trigger to function on.

Rupture triggers

Coronary plaques are constantly stressed by a variety of biomechanical and haemodynamic forces that may precipitate or "trigger" rupture of vulnerable plaques [3].

Blood pressure

The luminal pressure induces both circumferential tension in and radial compression of the vessel wall. The circumferential wall tension (tensile stress) caused by the blood pressure is given by Laplace's law that relates luminal pressure and radius to wall tension: the higher the blood pressure and the larger the luminal diameter, the more tension develops in the wall. If components within the wall (soft gruel, for example) are unable to bear the imposed load, the stress is redistributed to adjacent structures (fibrous cap over gruel, for example) where it may be critically concentrated [39, 40, 68]. Importantly, the thickness of the fibrous cap is most critical for the peak circumferential stress: the thinner the fibrous cap, the higher stress develops in it [39].

Pulse pressure

The propagating pulse wave causes cyclic changes in lumen size and shape with deformation and bending of plaques, particularly the "soft" ones. Eccentric plaques typically bend at their edges, ie, at the junction between the stiff plaque and the more compliant plaque-free vessel wall. Cyclic bending may in the long term weaken these points leading to unprovoked "spontaneous" fatigue disruption, while a sudden accentuated bending may "trigger" rupture of a weakened cap.

Heart contraction

The coronary arteries tethered to the surface of the beating heart undergo cyclic longitudinal deformations by axial bending (flexion) and stretching, particularly the left anterior descending coronary artery [69]. Angiographically, the angle of flexion was recently found to correlate with subsequent lesion progression, but the coefficient of correlation was low [69]. Like circumferential bending, a sudden accentuated longitudinal flexion may "trigger" plaque disruption, while long term cyclic flexion may "fatigue" and weaken the plaque.

Spasm

Plaque rupture and vasospasm do frequently coexist, but the former most likely gives rise to the latter rather than vice versa [70]. Onset of myocardial infarction is uncommon during or shortly after drug-induced spasm of even severely diseased coronary arteries, indicating that spasm infrequently precipitates plaque disruption and/or luminal thrombosis.

Fluid dynamic stress

High blood velocity within stenotic lesions may shear the endothelium away, but whether high haemodynamic shear alone may disrupt a stenotic plaque is questionable. Haemo-

dynamic stresses are usually much smaller than mechanical stresses imposed by blood and pulse pressures.

Thrombotic response to plaque rupture

Coronary thrombosis is the result of a dynamic interplay between the arterial wall and the flowing blood. About 75 % of thrombi responsible for acute coronary syndromes are precipitated by plaque disruption whereby thrombogenic material is exposed to the flowing blood (Figure 1) [2]. Superficial plaque erosion without frank disruption, ie, no deep injury, are found beneath the remaining thrombi [40, 71], usually in combination with a severe atherosclerotic stenosis.

There are three major determinants for the thrombotic response to plaque disruption/erosion: 1) character and extent of exposed thrombogenic plaque materials (thrombogenic substrates); 2) degree of stenosis and surface irregularities (local flow disturbances); and 3) thrombotic-thrombolytic equilibrium at the time of plaque disruption/erosion (systemic thrombotic tendency).

The thrombotic response to plaque disruption is dynamic; thrombosis/rethrombosis and thrombolysis/embolization occur simultaneously in many patients with acute coronary syndromes, with or without concomitant vasospasm, causing intermittent flow obstructions [2]. The initial flow obstruction is usually caused by platelet aggregation but fibrin is important for subsequent stabilization of the early and fragile platelet thrombus. Therefore, both platelets and fibrin play a role in the evolution of a persisting coronary thrombus.

Clinical aspects

Plaque disruption itself is asymptomatic, and also the associated rapid plaque growth is usually clinically silent. It is probably the most important mechanism responsible for the unpredictable, sudden and nonlinear progression of coronary lesions frequently observed angiographically [72].

The occurrence and course of coronary atherosclerosis and IHD are largely unpredictable. For individuals with the same number and degree of stenoses evaluated angiographically, some live for years without any symptoms while others are severely handicapped by angina pectoris, experience life-threatening heart attacks or die unexpectedly. The composition of plaques (plaque type) is most important for clinical presentation and outcome in IHD.

Davies et al. categorized the plaque type in 54 men with stable angina and found that 60 % of the plaques were fibrous and 40 % were lipid-rich [73]. More interestingly, all the plaques were fibrous in 15 % of the patients and not a single plaque with a large lipid pool was found in as many as 1/3 of the patients. Apparently, many patients with stable angina lack the appropriate pathoanatomic substrate for plaque disruption and may, consequently, be at low risk of an acute coronary syndrome. It should be noted, however, that in the same patient individual plaques usually differ significantly, and the composition of one plaque does not predict the composition of a nearby plaque in the same artery. Recently, we observed that inflammation of the cap and shoulders is a local and common phenomenon in atherosclerotic coronary and femoral arteries [74]. Inflammation was observed in the majority of arteries and not individually related. The latter observation may imply that local inflammation alone may not be a specific marker for plaque vulnerability.

Studies on determinants of plaque rupture were all performed retrospectively. The predictive value of a thin fibrous cap/local inflammation or a large atheromateus core for a plaque to rupture is unknown. Local determinants of plaque rupture have not been studied prospectively which is mainly due to the fact that animal models that show plaque ruptures are lacking. In the future, it may be possible to identify vulnerable plaques by imaging techniques and follow their fate prospectively [75].

Acute coronary syndromes

Following plaque disruption, haemorrhage into the plaque, luminal thrombosis and/or vasospasm may cause sudden flow obstruction, giving rise to new or changing symptoms. The culprit lesion is frequently "dynamic" causing intermittent flow obstruction, and the clinical presentation and the outcome depend on the severity and duration of myocardial ischaemia. A nonocclusive or transiently occlusive thrombus most frequently underlies primary unstable angina with pain at rest and non-ST-elevation infarction (often but not always subendocardial) while a more stable and occlusive thrombus is most frequently seen in ST-elevation infarction (often but not always transmural) – overall modified by vascular tone and collateral flow [1]. The lesion

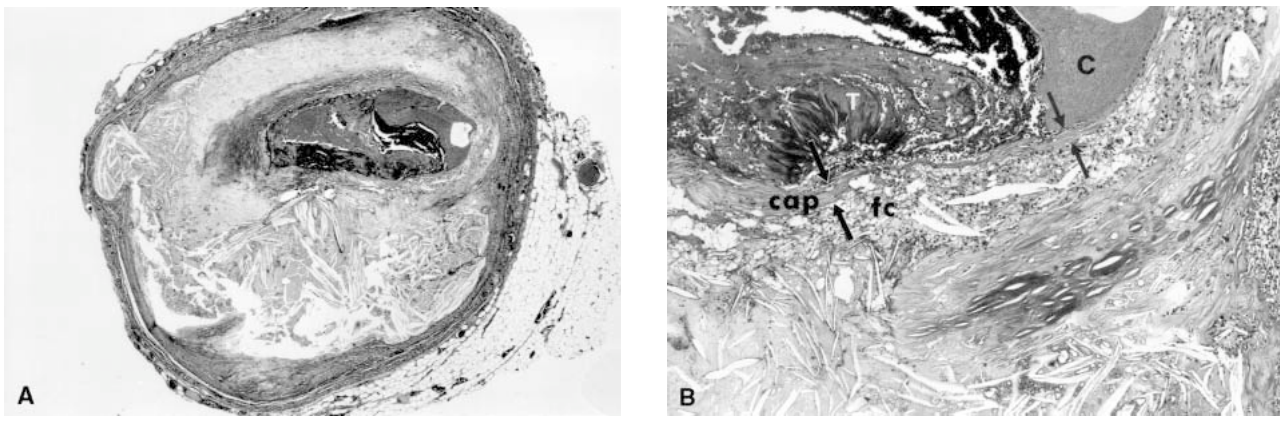

Figure 1: Plaque disruption and thrombosis. **A.** A stenotic coronary plaque containing a huge atheromatous core that is separated from the vascular lumen by a very thin cap of fibrous tissue, ie, a "vulnerable plaque". The fibrous cap is disrupted with superimposed non-occlusive luminal thrombosis. **B.** Higher magnification of the plaque-thrombus interface. The fibrous cap is very thin (between arrows) and heavily infiltrated by foam cells (fc), probably of macrophage origin. C: contrast medium injected post mortem; T: thrombus

responsible for out-of-hospital cardiac arrest or sudden death is often similar to that of unstable angina: a disrupted plaque with superimposed nonocclusive thrombosis [1, 67].

Conclusions

Atherosclerosis without thrombosis is in general a benign disease. However, acute thrombosis frequently complicates the course of coronary atherosclerosis, causing unstable angina, myocardial infarction and sudden death. The mechanism responsible for the sudden conversion of a stable disease to a life-threatening condition is usually plaque disruption with superimposed thrombosis. The risk of plaque disruption depends more on plaque vulnerability and thrombogenicity than on plaque size or stenosis severity; plaque vulnerability predisposes the plaque to rupture and rupture triggers may precipitate it. The challenge of today is to identify and treat the dangerous vulnerable plaques responsible for the life-threatening acute heart attacks – to find and treat only angina-producing stenotic lesions is no longer enough. Culprit lesion-based interventions usually eliminate anginal pain but do not substantially improve the long-term outcome, because myocardial infarction and death depend more on coexisting nonsymptomatic vulnerable plaques than on stenotic angina-producing lesions. For prevention and treatment, a systemic approach that addresses all coronary plaques will prove to be most rewarding.

Acknowledgement

G. Pasterkamp is a fellow of the Catharijne Foundation and supported by the Inter Cardiology University Institute of the Netherlands.

References

1. Fuster V, Badimon L, Badimon J, Chesebro JH. The pathogenesis of coronary artery disease and the acute coronary syndromes. N Eng J Med 1992; 326: 242–50 and 310–8.
2. Falk E. Coronary thrombosis: Pathogenesis and clinical manifestations. Am J Cardiol. 1991; 68 (suppl B): 28B–35B.
3. Falk E, Shah PK, Fuster V. Coronary plaque disruption. Circulation 1995; 92: 657–71.
4. Fernandez-Ortiz A, Badimon JJ, Falk E, Fuster V, Meyer B, Mailhac A, Weng D, Shah PK, Badimon L. Characterization of the relative thrombogenicity of atherosclerotic plaque components: Implications for consequences of plaque rupture. J Am Coll Cardiol 1994; 23: 1562–9.
5. Moreno PR, Bernardi VH, López-Cuéllar J, Murcia AM, Palacios IF, Gold HK, Mehran R, Sharma SK, Nemerson Y, Fuster V, Fallon JT. Macrophages, smooth muscle cells, and tissue factor in unstable angina. Implications for cell-mediated thrombogenicity in acute coronary syndromes. Circulation 1996; 94: 3090–7.
6. Toschi V, Gallo R, Lettino M et al. Tissue factor modulates the thrombogenicity of human atherosclerotic plaque. Circulation 1997; 95: 594–9.
7. Armstrong ML, Heistad DD, Marcus ML, Megan MB, Piegors DJ. Structural and hemodynamic responses of peripheral arteries of macaque monkeys to atherogenic diet. Arteriosclerosis 1985; 5: 336–46.
8. Glagov S, Weisenberg E, Zarins CK, Stankunavicius R, Kolettis G. Compensatory enlargement of human atherosclerotic coronary arteries. N Engl J Med 1987; 316: 1371–5.
9. Pasterkamp G, Wensing PJW, Post MJ, Hillen B, Mali WPTM, Borst C. Paradoxical arterial wall shrinkage contributes to luminal narrowing of human atherosclerotic femoral arteries. Circulation 1995; 91: 1444–9.
10. Pasterkamp G, Borst C, Post MJ, Mali WPTM, Wensing PJW, Gussenhoven EJ, Hillen B. Atherosclerotic arterial remodeling in the superficial femoral artery: individual variation in local compensatory enlargement response. Circulation 1996; 93: 1818–25.
11. Pasterkamp G, Schoneveld AH, van Wolferen WA, Hillen B, Clarijs RJG, Haudenschild CC, Borst C. The impact of atherosclerotic arterial remodeling on percentage luminal stenosis varies widely within the arterial system: a post mortem study. Arterioscler Thromb Vasc Biol 1997; 17: 3057–63.
12. Nishioka T, Luo H, Eigler NL, Berglund H, Kim C-J, Siegel RJ. Contribution of inadequate compensatory enlargement to development of human coronary artery stenosis: an in vivo intravascular ultrasound study. J Am Coll Cardiol 1996; 27: 1571–6.
13. Mann JM, Davies MJ. Vulnerable plaque. Relation of characteristics to degree of stenosis in human coronary arteries. Circulation 1996; 94: 928–31.
14. Kragel AH, Reddy SG, Wittes JT, Roberts WC. Morphometric analysis of the composition of atherosclerotic plaques in the four major epicardial coronary arteries in acute myocardial infarction and in sudden coronary death. Circulation 1989; 80: 1747–56.
15. Kragel AH, Reddy SG, Wittes JT, Roberts WC. Morphometric analysis of the composition of coronary arterial plaques in isolated unstable angina pectoris with pain at rest. Am J Cardiol 1990; 66: 562–7.
16. Lafont A, Libby P. The smooth muscle: sinner or saint in restenosis and the acute coronary syndromes? J Am Coll Cardiol 1998; 32: 283–5.
17. Small DM. Progression and regression of atherosclerotic lesions. Insights from lipid physical biochemistry. Arterioscl 1988; 8: 103–29.
18. Guyton JR, Klemp KF. The lipid-rich core region of human atherosclerotic fibrous plaques. Prevalence of small lipid droplets and vesicles by electron microscopy. Am J Pathol 1989; 134: 705–17.
19. Geng Y-J, Libby P. Evidence for apoptosis in advanced human atheroma. Am J Pathol 1995; 147: 251–66.
20. Ball RY, Stowers EC, Burton JH, Cary NRB, Skepper JN, Mitchinson MJ. Evidence that the death of macrophage foam cells contributes to the lipid core of atheroma. Atheroscl 1995; 114: 45–54.
21. Witztum JL. The oxidation hypothesis of atherosclerosis. Lancet 1994; 344: 793–5.
22. Wight TN. Cell biology of arterial proteoglycans. Arterioscl 1989; 9: 1–20.
23. Guyton JR, Klemp KF. Development of the atherosclerotic core region: chemical and ultrastructural analysis of microdissected atherosclerotic lesions from human aorta. Arterioscl Thromb 1994; 14: 1305–14.
24. Ambrose JA, Tannenbaum, Alexopoulos D et al. Angiographic progression of coronary artery disease and the development of myocardial infarction. J Am Coll Cardiol 1988; 12: 56–62.
25. Little WC, Constantinescu M, Applegate RJ et al. Can coronary angiography predict the site of a subsequent myocardial infarction in patients with mild-to-moderate coronary artery disease? Circulation 1988; 78: 1157–66.
26. Pasterkamp G, Schoneveld AH, van der Wal AC, Haudenschild CC, Clarijs RJG, Becker AE, Hillen B, Borst C. The relation of arterial geometry with luminal narrowing and plaque vulnerability: the remodeling paradox. J Am Coll Cardiol 1998; 32: 655–62.
27. Smits PC, Pasterkamp G, de Jaegere PJ, Eefting FD, Stella PR, Borst C. Coronary artery disease: arterial remodeling and clinical presentation. Heart 1999; 82: 461–4.
28. Mc Pherson DD, Sirna SJ, Hiratzka LF, Thorpe L, Armstrong ML, Marcus ML, Kerber RE. Coronary arterial remodeling studied by high frequency epicardial echocardiography: an early compensatory mechanism in patients with obstructive coronary atherosclerosis. J Am Coll Cardiol 1991; 17: 79–86.
29. Pasterkamp G, Borst C, Gussenhoven EJ, Mali WPTM, Post MJ, The SHK, Reekers JA, van der Berg FA. Remodeling of de novo atherosclerotic lesions in femoral arteries: impact on the mechanism of balloon angioplasty. J Am Coll Cardiol 1995; 26: 422–8.
30. Hermiller JB, Tenaglia AN, Kisslo KB, Phillips HR, Bashore TM, Stack RS, Davidson CJ. In vivo validation of compensatory enlargement of atherosclerotic coronary arteries. Am J Cardiol 1993; 71: 665–8.
31. Ge J, Erbel R, Zamorano J, Koch L, Kearney P, Görge G, Gerber TC, Meyer J. Coronary artery remodeling in atherosclerotic disease: an intravascular ultrasonic study in vivo. Cor Art Dis 1993; 4: 981–6.
32. Losordo DW, Rosenfield K, Kaufman J, Pieczek A, Isner JM. Focal compensatory enlargement of human arteries in response to progressive atherosclerosis. Circulation 1994; 89: 2570–7.
33. Steinke W, Els T, Hennerici M. Compensatory carotid artery dilatation in early atherosclerosis. Circulation 1994; 89: 2578–81.
34. Gertz SD, Roberts WC: Hemodynamic shear force in rupture of coronary arterial atherosclerotic plaques. Am J Cardiol 1990; 66: 1368–72.
35. Davies MJ, Richardson PD, Woolf N, Katz DR, Mann J. Risk of thrombosis in human atherosclerotic plaques: role of extracellular lipid, macrophage, and smooth muscle cell content. Br Heart J 1993; 69: 377–81.
36. Casscells W, Hathorn B, David M, Krabach T, Vaughn WK, McAllister HA, Bearman G, Willerson JT. Thermal detection of cellular infiltrates in living atherosclerotic plaques: possible implications for plaque rupture and thrombosis. Lancet 1996; 347: 1447–9.
37. Wagner WD, St.Clair RW, Clarkson TB, Connor JR. A study of atherosclerosis regression in Macaca mulatta: III. Chemical changes in arteries from animals with atherosclerosis induced for 19 months and regressed for 48 months at plasma cholesterol concentrations of 300 or 200 mg/dl. Am J Pathol 1980; 100: 633–50.
38. Loree HM, Tobias BJ, Gibson LJ, Kamm RD, Small DM, Lee RT: Mechanical properties of model atherosclerotic lesion lipid pools. Arterioscl Thromb 1994; 14: 230–4.
39. Loree HM, Kamm RD, Stringfellow RG, Lee RT. Effects of fibrous cap thickness on peak circumferential stress in model atherosclerotic vessels. Circ Res 1992; 71: 850–8.
40. Richardson PD, Davies MJ, Born GVR. Influence of plaque configuration and stress distribution on fissuring of coronary atherosclerotic plaques. Lancet 1989; ii: 941–4.
41. Falk E. Plaque rupture with severe pre-existing stenosis precipitating coronary thrombosis. Characteristics of coronary atherosclerotic plaques underlying fatal occlusive thrombi. Br Heart J 1983; 50: 127–34.
42. van der Wal AC, Becker AE, van der Loos CM, Das PK. site of intimal rupture or erosion of thrombosed coronary atherosclerotic plaques is characterized by an inflammatory process irrespective of the dominant plaque morphology. Circulation 1994; 89: 36–44.
43. Poston RN, Haskard DO, Coucher JR, Gall NP, Johnson-Tidey RR. Expression of intercellular adhesion molecule-1 in atherosclerotic plaques. Am J Pathol 1992; 140: 665–73.
44. Lendon CL, Davies MJ, Born GVR, Richardson PD: Atherosclerotic plaque caps are locally weakened when macrophages density is increased. Atheroscl 1991; 87: 87–90.
45. Moreno PR, Falk E, Palacios IF, Newell JB, Fuster V, Fallon JT. Macrophage infiltration in acute coronary syndromes: implications for plaque rupture. Circulation 1994; 90: 775–8.

46. Galis ZS, Galina Sukhova GK, Kanshofer R et al. Macrophage foam cells from experimental atheroma constitutively produce matrix-degrading metalloproteinases. Proc Natl Acad Sci USA 1995; 92: 402–6.
47. Matrisian LM. The matrix degrading metalloproteinases. Bioessays 1992; 14: 455–63.
48. Galis ZS, Sukhova GK, Lark MW, Libby P. Increased expression of matrix metalloproteinases and matrix degrading activity in vulnerable regions of human atherosclerotic plaques. J Clin Invest 1994; 94: 2493–503.
49. Lee RT, Schoen FJ, Loree HM, Lark MW, Libby P. Circumferential stress and matrix metalloproteinase-1 in human coronary atherosclerosis. Implications for plaque rupture. Arterioscl Thromb Vasc Biol 1996; 16: 1070–3.
50. Freestone T, Turner RJ, Coady A, Highman DJ, Greenhalgh RM, Powell JT. Inflammation and matrix metalloproteinases in the enlarging abdominal aortic aneurysm. Arterioscl Thromb Vasc Biol 1995; 15: 1145–51.
51. Patel MI, Melrose J, Ghosh P, Appleberg M. Increased synthesis of matrix metalloproteinases by aortic smooth muscle cells is implicated in the etiopathogenesis of abdominal aortic aneurysms. J Vasc Surg 1996; 24: 82–92.
52. Galis ZS, Asanuma K, Godin D, Meng X. N-Acetyl-cysteine decreases the matrix-degrading capacity of macrophage-derived foam cells. New target for antioxidant therapy? Circulation 1998; 97: 2445–53.
53. Davies MJ. Reactive oxygen species, metalloproteinases, and plaque stability. Circulation 1998; 97: 2382–93.
54. Kaartinen M, Penttilä A, Kovanen PT. Accumulation of activated mast cells in the shoulder region of human coronary atheroma, the predilection site of atheromatous rupture. Circulation 1994; 90: 1669–78.
55. Kovanen PT, Kaartinen M, Paavonen T. Infiltrates of activated mast cells at the site of coronary atheromatous erosion or rupture in myocardial infarction. Circulation 1995; 92: 1084–8.
56. Schonbeck U, Mach F, Sukhova GK, Murphy C, Bonnefoy JY, Fabunmi RP, Libby P. Regulation of matrix metalloproteinase expression in human vascular smooth muscle cells by T-lymphocytes. A role for CD40 signaling in plaque rupture. Circ Res 1997; 81: 448–54.
57. Libby P. The molecular bases of the acute coronary syndromes. Circulation 1995; 91: 2844–50.
58. Kol A, Libby P: The mechanisms by which infectious agents may contribute to atherosclerosis and its clinical manifestations. Trends Cardiovasc Med 1998; 8: 191–9.
59. Ridker PM: Inflammation, infection, and cardiovascular risk how good is the clinical evidence? Editorial. Circulation 1998; 97: 1671–4.
60. Muhlestein JB, Hammond EH, Carlquist JF et al. Increased incidence of Chlamydia species within the coronary arteries of patients with symptomatic atherosclerotic versus other forms of cardiovascular disease. J Am Coll Cardiol 1996; 27: 1555–61.
61. Gurfinkel E, Bozovich G, Daroca A. Randomised trial of roxithromycin in non-Q-wave coronary syndromes: ROXIS pilot study. Lancet 1997; 350: 404–7.
62. Gupta S, Leatham EW, Carrington D, Mendall MA, Kaski JC, Camm J. Elevated Chlamydia pneumoniae antibodies, cardiovascular events, and azithromycin in male survivors of myocardial infarction. Circulation 1997; 96: 404–7.
63. Ferguson JJ. Meeting highlights: 47th annual scientific sessions of the American College of Cardiology. Circulation 1998; 97: 2377–81.
64. Wilcox JN, Smith KM, Schwartz SM, Gordon D. Localization of tissue factor in the normal vessel wall and in the atherosclerotic plaque. Proc Natl Acad Sci USA 1989; 86: 2839–43.
65. Ardissino D, Merlini PA, Ariens R, Coppola R, Bramucci E, Mannucci PM. Tissue-factor antigen and activity in human coronary atherosclerotic plaques. Lancet 1997; 349: 769–71.
66. Davies MJ, Bland JM, Hangartner JRW, Angelini A, Thomas AC: Factors influencing the presence or absence of acute coronary artery thrombi in sudden ischaemic death. Eur Heart J 1989; 10: 203–8.
67. Davies MJ, Thomas A. Thrombosis and acute coronary artery lesions in sudden cardiac ischemic death. N Engl J Med 1984; 310: 1137–40.
68. Cheng GC, Loree HM, Kamm RD, Fishbein MC, Lee RT. Distribution of circumferential stress in ruptured and stable atherosclerotic lesions. A structural analysis with histopathological correlation. Circulation 1993; 87: 1179–87.
69. Stein PD, Hamid MS, Shivkumar K, Davis TP, Khaja F, Henry JW. Effects of cyclic flexion of coronary arteries on progression of atherosclerosis. Am J Cardiol 1994; 73: 431–7.
70. Bogaty P, Hackett D, Davies G, Maseri A. Vasoreactivity of the culprit lesion in unstable angina. Circulation 1994; 90: 5–11.
71. Farb A, Burke AP, Tang AL, Liang Y, Mannan P, Smialek J, Virmani R. Coronary plaque erosion without rupture into a lipid core: A frequent cause of coronary thrombosis in sudden coronary death. Circulation 1996; 93: 1354–63.
72. Bruschke AVG, Kramer JR, Bal ET, Haque IU, Detrano RC, Goormastic M. The dynamics of progression of coronary atherosclerosis studied in 168 medically treated patients who underwent coronary arteriography three times. Am Heart J 1989; 117: 296–305.
73. Hangartner JRW, Charleston AJ, Davies MJ, Thomas AC. Morphological characteristics of clinically significant coronary artery stenosis in stable angina. Br Heart J 1986; 56: 501–8.
74. Pasterkamp G, Schoneveld AH, van der Wal AC, Hijnen DJ, van Wolveren WJA, Plomp S, Teepen HLJM, Borst C. Inflammation of the atherosclerotic cap and shoulder of the plaque is a common and locally observed feature in unruptured plaques of femoral and coronary aretries. Arterioscl Thromb Vasc Biol 1999; 19: 54–8.
75. Vallabhajosula S, Fuster V. Atherosclerosis:imaging techniques and the evolving role of nuclear medicine. J Nucl Med 1997; 11: 1788–94.

Mitteilungen aus der Redaktion

Besuchen Sie unsere

zeitschriftenübergreifende Datenbank

☑ **Bilddatenbank** ☑ **Artikeldatenbank** ☑ **Fallberichte**

e-Journal-Abo

Beziehen Sie die elektronischen Ausgaben dieser Zeitschrift hier.

Die Lieferung umfasst 4–5 Ausgaben pro Jahr zzgl. allfälliger Sonderhefte.

Unsere e-Journale stehen als PDF-Datei zur Verfügung und sind auf den meisten der marktüblichen e-Book-Readern, Tablets sowie auf iPad funktionsfähig.

☑ **Bestellung e-Journal-Abo**

Haftungsausschluss

Die in unseren Webseiten publizierten Informationen richten sich **ausschließlich an geprüfte und autorisierte medizinische Berufsgruppen** und entbinden nicht von der ärztlichen Sorgfaltspflicht sowie von einer ausführlichen Patientenaufklärung über therapeutische Optionen und deren Wirkungen bzw. Nebenwirkungen. Die entsprechenden Angaben werden von den Autoren mit der größten Sorgfalt recherchiert und zusammengestellt. Die angegebenen Dosierungen sind im Einzelfall anhand der Fachinformationen zu überprüfen. Weder die Autoren, noch die tragenden Gesellschaften noch der Verlag übernehmen irgendwelche Haftungsansprüche.

Bitte beachten Sie auch diese Seiten:

Impressum **Disclaimers & Copyright** **Datenschutzerklärung**