Journal für
Kardiologie
Austrian Journal of Cardiology
Österreichische Zeitschrift für Herz-Kreislauferkrankungen

Case Report: Patent Foramen Ovale and Pulmonary Embolism: Missed Chance to Prevent Stroke and Myocardial Infarction

Noti L, Garachemani A, Heule K
Meier B

Journal für Kardiologie - Austrian Journal of Cardiology 2026; 33 (11-12), 237-239

Homepage:
www.kup.at/kardiologie
Online-Datenbank
mit Autoren-
und Stichwortsuche



ÖKG Österreichische Kardiologische Gesellschaft
Offizielles Partnerjournal der ÖKG

EUROPEAN SOCIETY OF CARDIOLOGY®
Member of the ESC-Editor's Club

Offizielles Organ des Österreichischen Herzfonds

ACVC Association for Acute CardioVascular Care
In Kooperation mit der ACVC

Indexed in ESCI part of Web of Science
Indexed in EMBASE

Krause & Pachernegg GmbH • Verlag für Medizin und Wirtschaft • A-3003 Gablitz
P.b.b. 02Z031105M, Verlagsort: 3003 Gablitz, Linzerstraße 177A/21 Preis: EUR 10,–

Medtronic

E2E 2027

WAVES OF INNOVATION

14.-16. Jänner 2027

Courtyard by Marriott Linz

EXPERT 2 EXPERT 2027

For personal use only. Not to be reproduced without permission of Krause & Pachernegg GmbH.

Patent Foramen Ovale and Pulmonary Embolism: Missed Chance to Prevent Stroke and Myocardial Infarction

L. Noti[1], A. Garachemani[2], K. Heule[2], B. Meier[2]

From [1]Localmed, Bern, and [2]Cardio Bern, Lindenhof Hospital, Bern, Switzerland

Abstract

Introduction: Any clinical event potentially related to a patent foramen ovale (PFO) should initiate a search for a PFO and closure of it, if present.

Case presentation: A 65-year-old female presented with unrelenting chest discomfort. She had a history of pulmonary embolism (PE) 11 years earlier. She also had previously suffered multiple cerebral infarctions, documented by magnetic resonance imaging for behavioral changes starting 3 years earlier. D-dimers and troponin were elevated at admission. Computer tomography revealed PE. Transthoracic echocardiography documented antero-apical akinesia and a wall thrombus. Coronary angiography revealed an occlusion of the left anterior descendant coronary artery, with angiographic appearance of an embolus, that was recanalized percutaneously. Transesophageal echocardiography confirmed a PFO which was closed percutaneously.

Discussion: The sequence of events suggests PE 11 years ago followed by cerebral embolism that occurred about 3 years ago as a consequence of paradoxical emboli into cerebral arteries through the PFO; and now repeat PE happened, complicated by a subacute myocardial infarction (MI) by coronary embolism through the PFO. Clinicians should consider, search for, and treat if found a PFO with every systemic (e.g., cerebral) ischemic event deemed embolic. This prevents further paradoxical embolism and would have prevented the MI in this case. Ideally, venous thromboembolism should also constitute an indication to screen for a PFO. Such a policy would also have prevented the cerebral events in the patient at stake.

Introduction

The patent foramen ovale (PFO) is a valve-like interatrial gap between septum primum and septum secundum. It is present in about 27% of people [1].

Paradoxical embolism describes a condition in which a thrombus passes from the venous into the arterial circulation which typically happens through a PFO [2]. It was clinically first described in 1877 by Conheim, a German pathologist [3]. Upon autopsy of a young woman who succumbed to a stroke, he found thrombi in leg veins, a huge PFO, and emboli in cerebral arteries.

Paradoxical embolism can lead to occlusions in cerebral, coronary, ocular, visceral, or peripheral arteries. Already small emboli can cause significant ischemic events in the former three. The blood volume to the brain at rest amounts to roughly three times that of the coronary arteries. Hence, per three cerebral events by paradoxical embolism one myocardial infarction (MI) is likely to occur [4].

In patients with a cryptogenic stroke, the incidence of a PFO was found higher than in the normal population (40% vs. 25%) [5]. Strangely, field studies failed to prove a significantly increased stroke risk in patients with a PFO [6]. This is presumably due to the fact that in the respective studies the PFO was screened for with unsensitive techniques. This blunted the difference because of the many unidentified PFO carriers in the comparison group.

Noncerebral paradoxical embolism is reported relatively rarely [7–15]. Regarding visceral and peripheral arteries, this can be explained by the fact that only large thrombi can cause harm. Coronary arteries are sensitive to small thrombi like cerebral arteries [7–11]. Massive underreporting of embolic events must be assumed, based on the mentioned cerebral to coronary arteries blood distribution of about 3:1. This ratio in no way correlates with the numbers of suspected PFO related cerebral and coronary embolic events. Add to this that PFO related cerebral embolic events have hitherto almost exclusively been suspected and diagnosed in the cryptogenic stroke population [16–18], although in old and sick patients, venous thromboembolism and consequently in patients with a PFO paradoxical strokes and MIs are more prevalent [19, 20].

Suffice it to state, embolic MIs mediated by a PFO are practically never screened for and, thus, all but systematically misdiagnosed [4].

Case presentation

A 65-year-old woman presented with nonrelenting chills at the emergency department. She reported slight pain in her left arm and complained that her heart was not doing well. Her past medical history was notable for pulmonary embolism (PE) 11 years earlier and a history of cerebrovascular insults diagnosed several months ago at magnetic resonance brain imaging, performed for symptoms having suddenly started three years earlier and having been putatively attributed to dementia or depression. There were old infarctions of the thalamus and two other regions.

Her current medication consisted of acetylsalicylic acid, statin, thyroid hormone, and antidepressant. Blood pressure was elevated at 159/108 mmHg. Heart rate and oxygen saturation were normal. The ECG showed a loss of the R-waves over the entire anterior wall. Cardiac injury biomarkers such as high sensitivity troponin and creatine kinase were elevated, as was D-dimer.



Figure 1: Computer tomography depicting pulmonary embolism (arrow).



Figure 2: Transesophageal echocardiography showing an immobile thrombus (arrows) at the akinetic apex of the left ventricle.

Due to the Wells Score [21] of 1 point and the elevated D-dimer, a computer tomography of the pulmonary arteries was performed. It revealed emboli in segmental and subsegmental pulmonary arteries (Figure 1).

The increased troponin and the ECG changes suggested a concomitant coronary problem. Nitroglycerin, unfractionated heparin, and ticagrelor were initiated. Transthoracic echocardiography was performed. In the area of the akinetic apex, an immobile thrombus was visualized and later confirmed by a transesophageal echocardiography (TEE, Figure 2). Coronary angiography was performed depicting an occlusion, suggesting an embolus, of the mid left anterior descendant coronary artery (LAD). It was recanalized by balloon angioplasty (Figure 3). The remaining coronary arteries were normal and smooth-walled, making a paradoxical embolic occlusion even more likely.

Intravenous heparinization was started and a TEE confirmed a PFO.

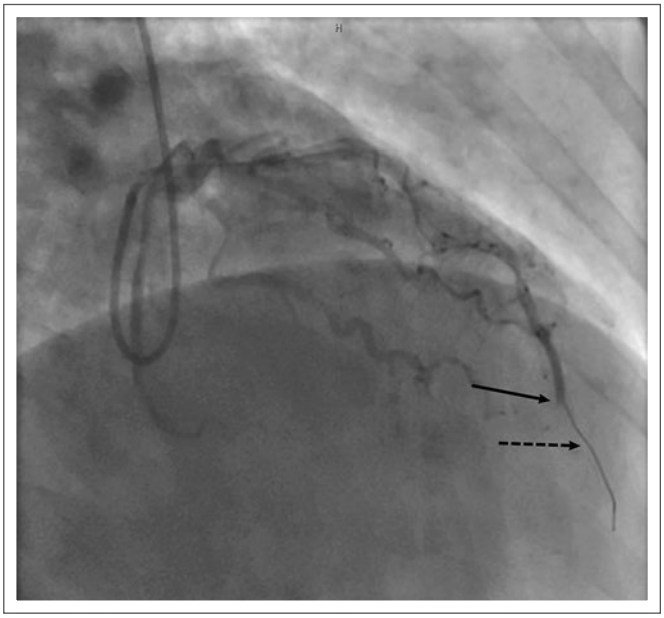

Figure 3: Embolic appearing occlusion of the mid left anterior descending coronary artery (solid arrow) . The dashed arrow shows a coronary guidewire that had been passed through the occlusion.

The patient was discharged on acetylsalicylic acid and a vitamin K antagonist (VKA). Consultation with hematology had advised against a direct oral anticoagulant due to lacking respective data in such a complex situation. Closure of the persistent foramen ovale with an Figulla Flex II 25 mm PFO occluder was performed shortly thereafter in an outpatient procedure. At this time, the LAD was found patent with normal appearance.

Screening for a prothrombotic disposition in the light of a positive family and personal history was postponed to a time when the VKA could be stopped. To obtain valid screening results, VKA therapy must be discontinued for two weeks. This was discussed during a follow-up appointment, but the patient decided against discontinuation, even if only for a short time. A control TEE had shown persistence of anterior hypokinesia of the left ventricle, disappearance of the apical thrombus, and complete closure of the PFO.

Discussion

The PFO is the most common mediator of paradoxical embolism. The case with repeated PE and most probably embolic occlusions of a coronary and several cerebral arteries highlights the importance of early screening for a PFO and prompt closure of it, if present. If a PFO had been searched for and closed earlier, i.e., when the cerebral symptoms started 3 years ago or when old cerebral infarcts were documented several months ago, the paradoxical embolic MI would have been prevented. Had the PFO been looked for, found, and occluded on the occasion of the first PE 11 years ago, the cerebral infarcts would also have been prevented.

In a multicenter study from 2022, patients undergoing PFO closure were examined [12]. The indication for PFO closure was mostly a cerebrovascular event (97%). In the group of patients who had a PFO closure after a noncerebral event, the prevalence of a previous or concurrent thrombotic event such as PE or venous thrombosis and arterial ischemic events such as MI or stroke was significantly higher. The authors concluded that the potential role of a PFO in a first cryptogenic embolic event is underestimated and that increased awareness can prevent systemic thromboembolic events.

There are three prerequisites for diagnosing paradoxical embolism: a venous source of the embolism (often too insignificant to be detectable), an intracardiac or pulmonary right to left shunt (typically a PFO, rarely an atrial septal defect [22] or a pulmonary arteriovenous fistula), and evidence of arterial embolism. In most cases, the diagnosis remains presumptive, unless an embolus can be documented in transit through the PFO [23]. Therefore, the true incidence of paradoxical embolism remains unknown [7].

A right to left shunt through a PFO occurs after a sustained or brief reversal of the pressure ratios between both atria (e.g., after a Valsalva maneuver or coughing) [24]. An increase in pressure in the pulmonary circulation, typically the case with PE, augments the probability of a right to left shunt and propagates paradoxical embolism in two ways, by clots passing through the right atrium on their way to the lungs and by increased likelihood of the PFO being open when this happens [25].

Two systemic reviews examined the risk of paradoxical embolism based on stroke in patients with PE. It was shown that the prevalence of stroke was six times higher (13% vs 2%) [25], respectively four times higher (20% vs 5%) [15], in patients with PFO than in those without. This provides a compelling argument to screen for a PFO in patients with venous thromboembolism and close it when found.

Several cases of MI caused by paradoxical embolisms have been reported. Not infrequently, coronary angiography depicts multiple embolic occlusions [7, 8, 10, 11, 13, 14, 22]. The incidence of embolic MIs is estimated at approximately 3% of all MIs [9]. Underestimation is obvious. Typically, an embolic event is only suspected if the coronary arteries look otherwise healthy. In the presence of atherosclerotic changes, embolic occlusion is practically never considered. This ignores the fact that paradoxical embolism through a PFO is more likely in old and sick than in young and healthy people, due to the higher propensity for venous thrombosis of the former [19, 20].

A left ventricular thrombus like the one found in the apex of the patient could be the source of direct embolism into cerebral or coronary arteries. However, the timeline suggests venous thrombosis with pulmonary and simultaneous paradoxical coronary embolism through the PFO causing embolic MI to the mid LAD with apical akinesia and subsequent wall thrombus.

In any patient with suspected paradoxical embolism, there is, of course, the possibility that a PFO is present but not causal. The European Society of Cardiology position paper from 2019 on clinical management of patients with PFO recommends excluding in particular atrial fibrillation, as this is an established cause for left circulation embolisms [5]. If no atrial fibrillation is detected, risk stratification with critical clinical judgment is recommended. The decision should be made on an interdisciplinary basis. However, a known PFO is always a potential culprit of systemic embolic events, be they in the past or the future. To eliminate a PFO is easy and practically risk-free. Hence, the PFO should be occluded in all cases in the sense of a mechanical vaccination against further paradoxical embolism [4].

Declaration

No conflicts of interest to declare.
The patient described in this case report has given informed consent for publication.
Author contributions: Lea Noti: preparation of manuscript; Ali Garachemani: clinical case management, revision of manuscript; Kai Heule: clinical case management, revision of manuscript; Bernhard Meier: revision of manuscript

References:

1. Hagen PT, Scholz DG and Edwards WD. Incidence and size of patent foramen ovale during the first decades of life: an autopsy study of 965 normal hearts. Mayo Clin Proc 1984; 59: 17–20.
2. Johnson BI. Paradoxical embolism. J Clin Pathol 1951; 4: 316–32.
3. Cohnheim J. Thrombose und Embolie: Vorlesung über allgemeine Pathologie. Ein Handbuch für Ärzte und Studierende. Hirschwald, Berlin; 1877.
4. Meier B. A cardiologist's perspective on patent foramen ovale associated conditions. Cardiol Clin 2024; 42: 547–57.
5. Pristipino C, Sievert H, D'Ascenzo F, Louis Mas J, Meier B, Scacciatella P, et al. European position paper on the management of patients with patent foramen ovale. General approach and left circulation thromboembolism. Eur Heart J 2019; 40: 3182–95.
6. Collado FMS, Poulin MF, Murphy JJ, Jneid H, Kavinsky CJ. Patent foramen ovale closure for stroke prevention and other disorders. J Am Heart Assoc 2018; 7: e007146.
7. Stortecky S, Cook S, Meier B, Togni M. Patent foramen ovale: a culpable pathway for myocardial infarction. J Am Coll Cardiol 2011; 58: 1923.
8. Kleber FX, Hauschild T, Schulz A, Winkelmann A, Bruch L. Epidemiology of myocardial infarction caused by presumed paradoxical embolism via a patent foramen ovale. Circ J 2017; 81: 1484–9.
9. Raphael CE, Heit JA, Reeder GS, Bois MC, Maleszewski JJ, Tilbury RT, Holmes DR, Jr. Coronary embolus: an underappreciated cause of acute coronary syndromes. JACC Cardiovasc Interv 2018; 11: 172–80.
10. Chen W, Yu Z, Li S, Wagatsuma K, Du B, Yang P. Concomitant acute myocardial infarction and acute pulmonary embolism caused by paradoxical embolism: a case report. BMC Cardiovasc Disord 2021; 21: 313.
11. Takemoto K, Nakamura M, Atagi K. Concomitant acute pulmonary embolism, myocardial infarction and ischemic stroke due to paradoxical embolism from a patent foramen ovale: a case report. Oxf Med Case Reports 2021; 2021: omab101.
12. Farjat-Pasos JI, Guedeney P, Houde C, Alperi A, Mesnier J, Cote M, Montalescot G, Rodes-Cabau J. Transcatheter closure of patent foramen ovale in patients with peripheral (noncerebrovascular) embolism. J Invasive Cardiol 2022; 34: E720–E725.
13. Liu Y, Yang Z, Sun X, Yang M, Zhang T, Li R, Wei Y, Cao H. Successful surgical treatment of impending paradoxical embolism with pulmonary embolism and myocardial infarction. J Cardiothorac Surg 2024; 19: 137.
14. Lamprou V, Daniels MJ, Read CD, Keshavarzi F. Paradoxical coronary embolism in Erdheim-Chester disease: invasive assessment and multidisciplinary management. Oxf Med Case Reports 2024; 2024: omae163.
15. Lucas TO, Schaustz EB, Dos Reis IJR, Lopes CG, Mendoca VS, Salluh JIF, Zukowski CN, Serafim RB. Risk of ischemic stroke in patients with pulmonary embolism and patent foramen ovale: A systematic review and meta-analysis. J Stroke Cerebrovasc Dis 2025; 34: 108157.
16. Giacoppo D, Caronna N, Frangieh AH, Michel J, Ando G, Tarantini G, Kasel AM, Capodanno D, Byrne RA. Long-term effectiveness and safety of transcatheter closure of patent foramen ovale compared with antithrombotic therapy alone: a meta-analysis of six randomised clinical trials and 3,560 patients with reconstructed time-to-event data. EuroIntervention 2018; 14: 857–67.
17. Vidale S, Russo F, Campana C, Agostoni E. Patent foramen ovale closure versus medical therapy in cryptogenic strokes and transient ischemic attacks: a meta-analysis of randomized trials. Angiology 2019; 70: 325–31.
18. Mas JL, Saver JL, Kasner SE, Nelson J, Carroll JD, Chatellier G, et al. Association of atrial septal aneurysm and shunt size with stroke recurrence and benefit from patent foramen ovale closure. JAMA Neurol 2022; 79: 1175–9.
19. Anderson FA, Jr., Wheeler HB, Goldberg RJ, Hosmer DW, Patwardhan NA, Jovanovic B, Forcier A, Dalen JE. A population-based perspective of the hospital incidence and case-fatality rates of deep vein thrombosis and pulmonary embolism. The Worcester DVT Study. Arch Intern Med 1991; 151: 933–8.
20. Martinez C, Cohen AT, Bamber L, Rietbrock S. Epidemiology of first and recurrent venous thromboembolism: a population-based cohort study in patients without active cancer. Thromb Haemostasis 2014; 112: 255–63.
21. Wells PS, Hirsh J, Anderson DR, Lensing AW, Foster G, Kearon C, et al. A simple clinical model for the diagnosis of deep-vein thrombosis combined with impedance plethysmography: potential for an improvement in the diagnostic process. J Intern Med 1998; 243: 15–23.
22. Cuculi F, Togni M, Meier B. Myocardial infarction due to paradoxical embolism in a patient with large atrial septal defect. J Invasive Cardiol 2009; 21: E184–6.
23. Koullias GJ, Elefteriades JA, Wu I, Jovin I, Jadbabaie F, McNamara R. Images in cardiovascular medicine. Massive paradoxical embolism: caught in the act. Circulation 2004; 109: 3056–7.
24. Dubourg O, Bourdarias JP, Farcot JC, Gueret P, Terdjman M, Ferrier A, Rigaud M, Bardet JC. Contrast echocardiographic visualization of cough-induced right to left shunt through a patent foramen ovale. J Am Coll Cardiol 1984; 4: 587–94.
25. Konstantinides S, Geibel A, Kasper W, Olschewski M, Blumel L, Just H. Patent foramen ovale is an important predictor of adverse outcome in patients with major pulmonary embolism. Circulation 1998; 97: 1946–51.

Corresponding author:
Dr. Lea Noti
Localmed
CH-3008 Bern, Schanzenstraße 4A
E-mail: noti@hin.ch

Mitteilungen aus der Redaktion

Besuchen Sie unsere Rubrik

☑ Medizintechnik-Produkte



Neues CRT-D Implantat
Intica 7 HF-T QP von Biotronik



Artis pheno
Siemens Healthcare Diagnostics GmbH



Philips Azurion:
Innovative Bildgebungslösung



Aspirator 3
Labotect GmbH



InControl 1050
Labotect GmbH

e-Journal-Abo

Beziehen Sie die elektronischen Ausgaben dieser Zeitschrift hier.

Die Lieferung umfasst 4–5 Ausgaben pro Jahr zzgl. allfälliger Sonderhefte.

Unsere e-Journale stehen als PDF-Datei zur Verfügung und sind auf den meisten der marktüblichen e-Book-Readern, Tablets sowie auf iPad funktionsfähig.

☑ Bestellung e-Journal-Abo

Haftungsausschluss

Die in unseren Webseiten publizierten Informationen richten sich **ausschließlich an geprüfte und autorisierte medizinische Berufsgruppen** und entbinden nicht von der ärztlichen Sorgfaltspflicht sowie von einer ausführlichen Patientenaufklärung über therapeutische Optionen und deren Wirkungen bzw. Nebenwirkungen. Die entsprechenden Angaben werden von den Autoren mit der größten Sorgfalt recherchiert und zusammengestellt. Die angegebenen Dosierungen sind im Einzelfall anhand der Fachinformationen zu überprüfen. Weder die Autoren, noch die tragenden Gesellschaften noch der Verlag übernehmen irgendwelche Haftungsansprüche.

Bitte beachten Sie auch diese Seiten:

Impressum **Disclaimers & Copyright** **Datenschutzerklärung**